

# A Cirrus HD-OCT Case Report

## Neovascular AMD

### The Patient

A 78 year old female Caucasian patient presented to the retinal department for a control visit. She did not notice any change in visual acuity of her right eye. Her left eye had been diagnosed with neovascular age-related macular degeneration about two years prior.

### The Details

Visual acuity examination was performed on both eyes and yielded 20/20 (right eye) and 20/100 (left eye). Dilated fundus examination of her right eye revealed central drusen, pigment epithelium irregularities, slight cystic changes within the foveal region and an intraretinal hemorrhage superior of the fovea. Fluorescein angiography and Cirrus™ HD-OCT were performed subsequently. A final diagnosis of a retinal angiomatous proliferation (RAP) was made.

On her left eye a large fibrovascular pigment epithelium detachment was diagnosed.

Despite the good visual acuity of her left eye the patient was very concerned and asked for treatment options. After a detailed discussion the conclusion was reached to treat the neovascular lesion with an intravitreal injection of Lucentis® (0.5 mg).

Two weeks later the patient presented with a stable visual acuity on her right eye. Dilated fundus examination showed a clinically dry fovea with remaining pigment epithelium irregularities.

### The HD Difference

The Cirrus HD-OCT scans show several pathologic changes. In the central 0° tomogram (Figure 1) the altered RPE can be seen clearly with a thickening of the neurosensory retina including intraretinal cysts.

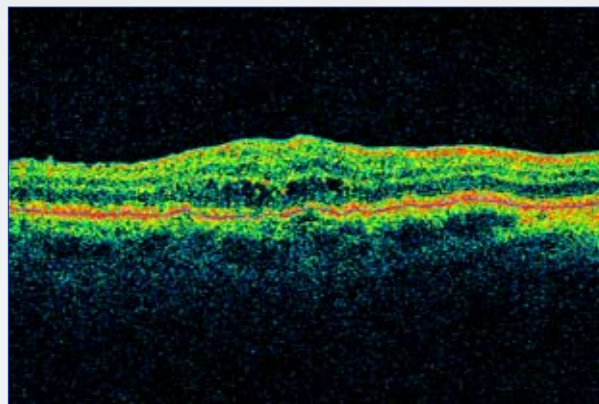


Figure 1

Figure 2 depicts the RPE layer map with significant irregularities.




Figure 2

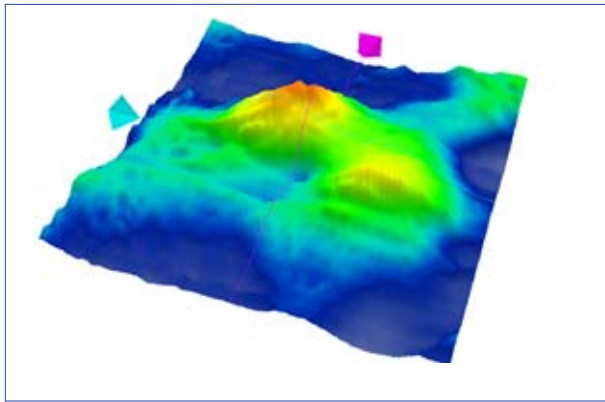


Figure 3

The HD retinal thickness map (Figure 3) shows the thickening of the retina with a peak superior to the foveola corresponding to the leakage area in the fluorescein angiogram (Figure 4).

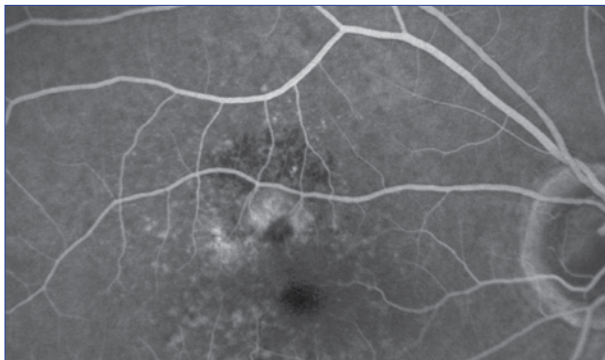


Figure 4

The LSO fundus image overlaid with the thickness map (Figure 5) provides additional information about the anatomical location of areas of increased thickness.

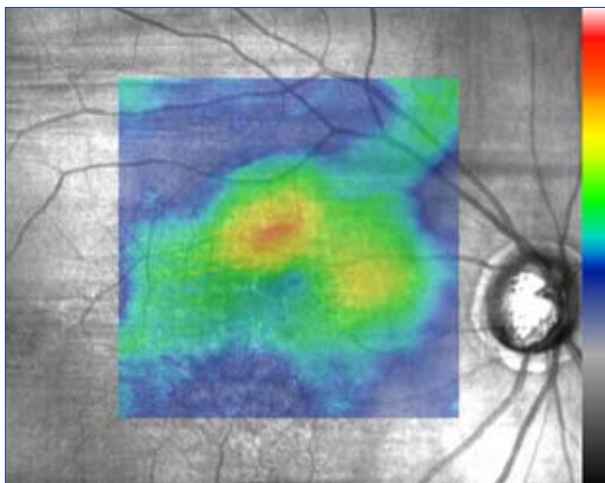


Figure 5

Figure 6 gives quantitative values of the scanned area which correspond to the known format of Stratus OCT™ systems.

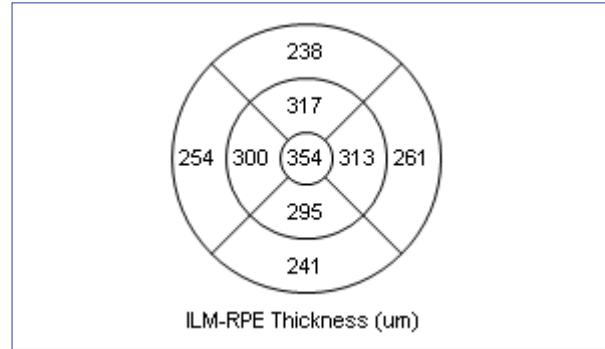


Figure 6

At the patient's follow-up visit two weeks later the treatment effect was seen in great detail. The thickness values of the central five subfields (Figure 7) show a marked decrease in retinal thickness corresponding to the thickness map (Figure 8). The view of the RPE layer map (Figure 9) shows stable conditions. Anatomical correlation of the LSO image with a thickness map (Figure 10) presents a decreased thickness specifically in the area surrounding the hemorrhage seen in the initial fluorescein angiogram.

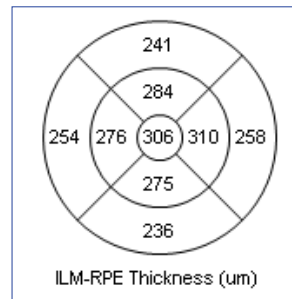


Figure 7




Figure 8




Figure 9

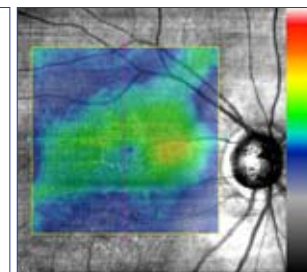


Figure 10