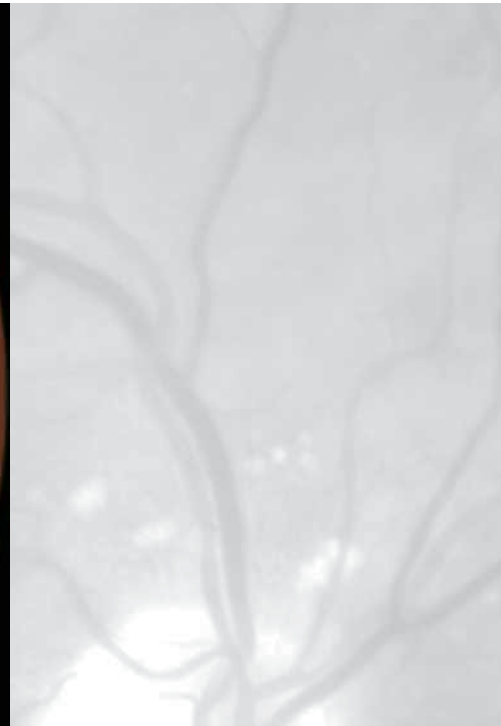
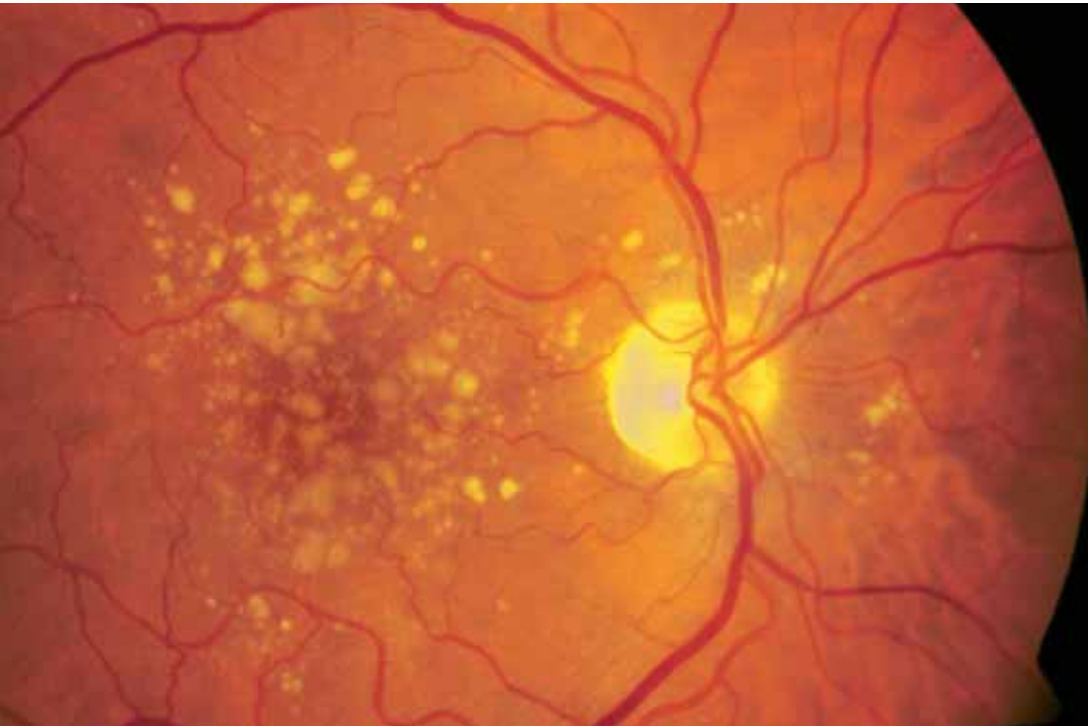
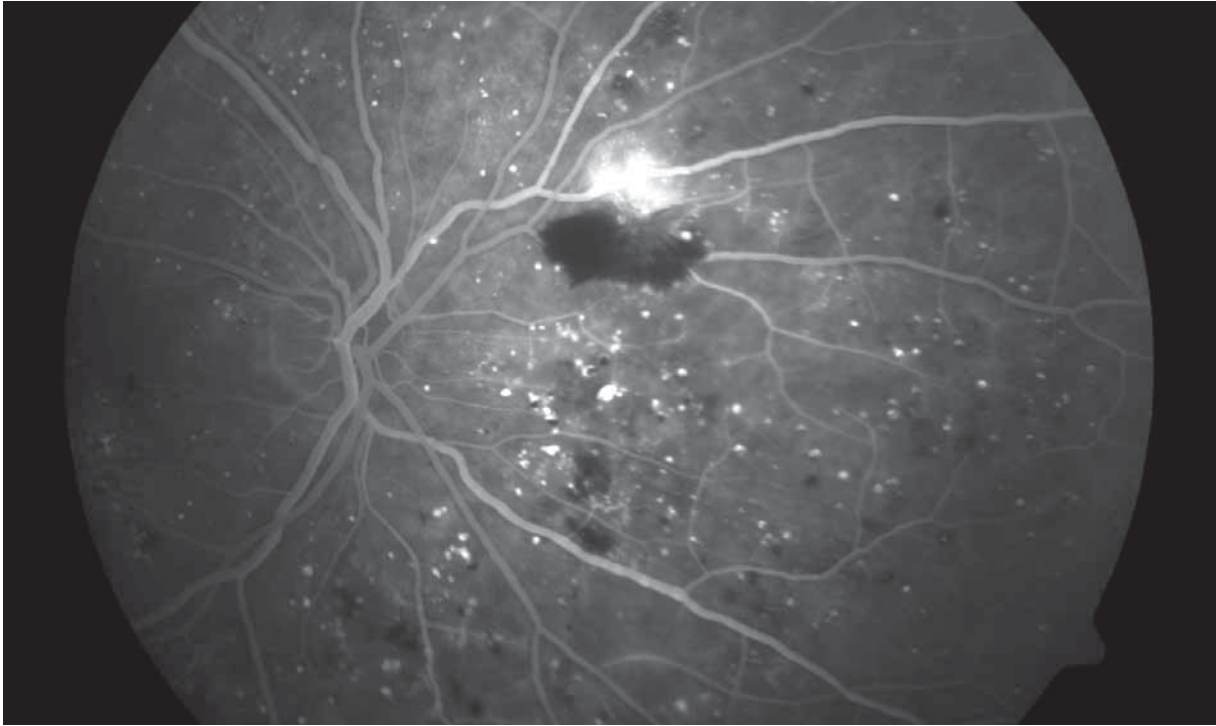


The Sensitive Sensor



The retina is the eye's optical sensor. It is an upstream area of the brain. It captures light stimuli and partly preprocesses them. The photosensitive receptors of the retina are the rods and cones, which differ in form and function. The ability to see color during the day is made possible by the 6 to 7 million cones, which are sensitive to blue, green or red light. The 120 million or so rods convey scotopic vision and contrast vision or, during the day, enable us to perceive movement at the periphery of our field of vision. The photoreceptors are distributed over the retina very unevenly. The color-sensitive cones are mainly arranged in the macular region. They achieve their greatest pack-

ing density in the center of the macula – in the area known as the fovea (approx. 170,000 cones/mm²). The fovea is where vision is at its sharpest. Outside the macula, cone density, and therefore also visual acuity, decrease rapidly. When we fixate an object in our environment, movements of our head and eyes ensure that the image of the object is located on the fovea. Loss of central vision in the macula therefore seriously impairs quality of life, although the person affected is not totally blind.



Attack on the retina

Retinal diseases are currently the main causes of blindness in industrial countries. The main retinal diseases are age-related macular degeneration (AMD) and diabetic retinopathy.

AMD is the main cause of an irreversible loss of central vision for people over the age of 50. In the case of the “wet form” of AMD, the abnormal formation of new blood vessels (choroidal neovascularization – CNV) leads relatively quickly to a loss of function in the macular region. The wet form may only account for around 10% of all AMD cases, but it is the cause of roughly 90% of all cases of blindness resulting from AMD. In the case of the “dry form” of AMD, deposits of waste material

(drusen) lead to a gradual deterioration of vision.

Diabetic retinopathy is the name given to pathological changes in the retinal vessels as a consequence of prolonged diabetes. After 20 years of suffering from the illness, 80 – 90% of diabetics are confronted with the onset of changes to their retinas. With diabetic retinopathy, there are several shades of distinction between non-proliferative retinopathy, characterized by microaneurysms (vessel swellings) as well as hemorrhaging, and the proliferative form that leads to the growth of new retinal vessels (neovascularizations). Given that proliferative retinopathy is highly likely to result in a massive loss of sight, treatment is absolutely essential at this stage of the disease.

AMD and diabetic retinopathy are closely linked to age. Since the population in industrial countries is aging all the time, diagnostics and therapy for these diseases constitute a challenge of the highest order for health policy.

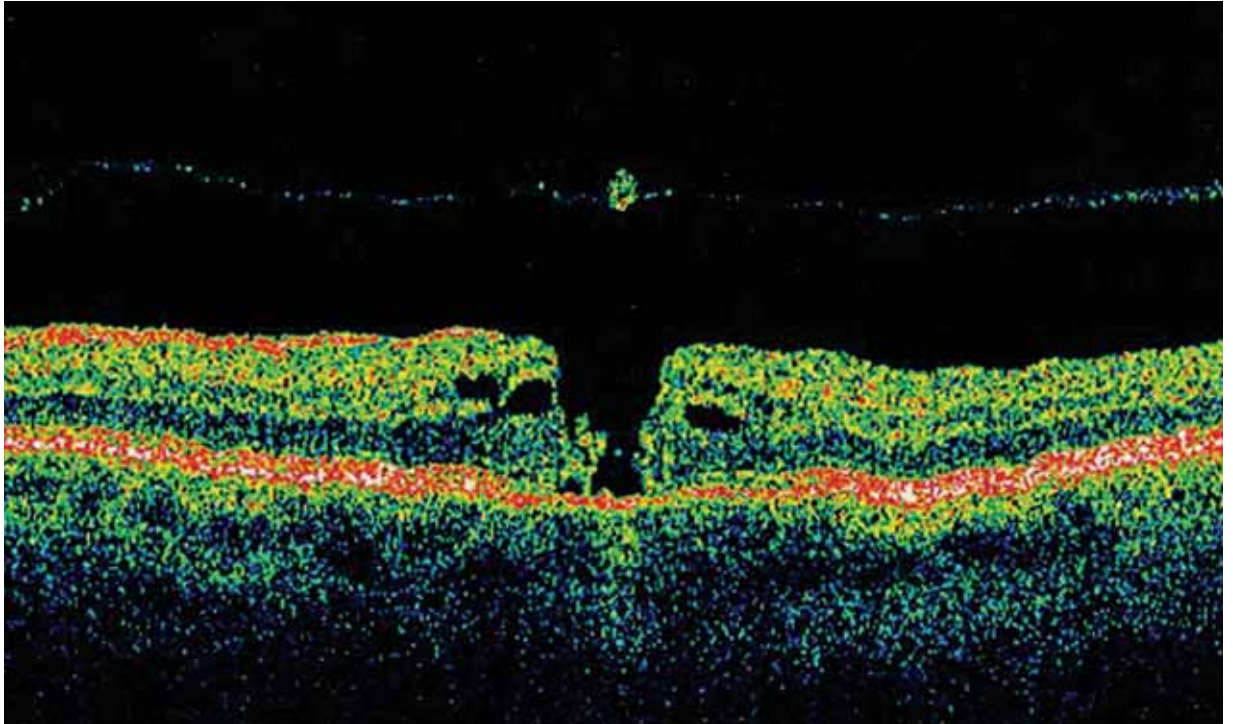
Diagnosis and follow-up

The diagnosis and monitoring of retinal diseases is essentially based on the qualitative and quantitative evaluation of any morphological changes in the retina, i.e. changes in shape, color or structure.

In the simplest scenario, this is done by means of a direct visual inspection of the “fundus” or back of the eye, e.g., using a handheld ophthalmoscope.

Left: Color image of a retina with drusen in the presence of AMD (age-related macular degeneration).

Right: Fluorescein angiogram of the retina in the presence of diabetic retinopathy.



Left: OCT cross-sectional image of a retina with macular hole.

Middle: VISULAS™ 532s photocoagulation laser.

Right: Stratus OCT optical coherence tomograph.

However, the documentation and quantitative analysis of the findings require special imaging instruments. The main imaging techniques used for this purpose are fundus photography with a fundus camera, scanning laser ophthalmoscopy (SLO) and optical coherence tomography (OCT). The fundus camera enables a true-to-nature reproduction of the fundus, which corresponds to the standard image of the retina obtained in ophthalmoscopy. Its versatility makes it an indispensable basic instrument for any retina specialist. Scanning laser ophthalmoscopes usually only supply monochrome images. Their strengths, however, lie in their ability to record the flow dynamics of the retinal vascular system (fluorescein angiography) and in the low light exposure of the patient during image capture.

With the OCT method, it is possible to obtain high-resolution virtual cross-sectional images (tomograms) of the retina (in vivo and totally contact-free) which come very close to histological cross-sectional images in terms of their detail to detail and information content ("optical biopsy"). The optical coherence tomograph is therefore an ideal complement to two-dimensional fundus photography, enabling a three-dimensional evaluation of the fundus. This innovative technique, introduced by Carl Zeiss in 1996, is regarded as the most significant advance in imaging fundus diagnostics in recent years.

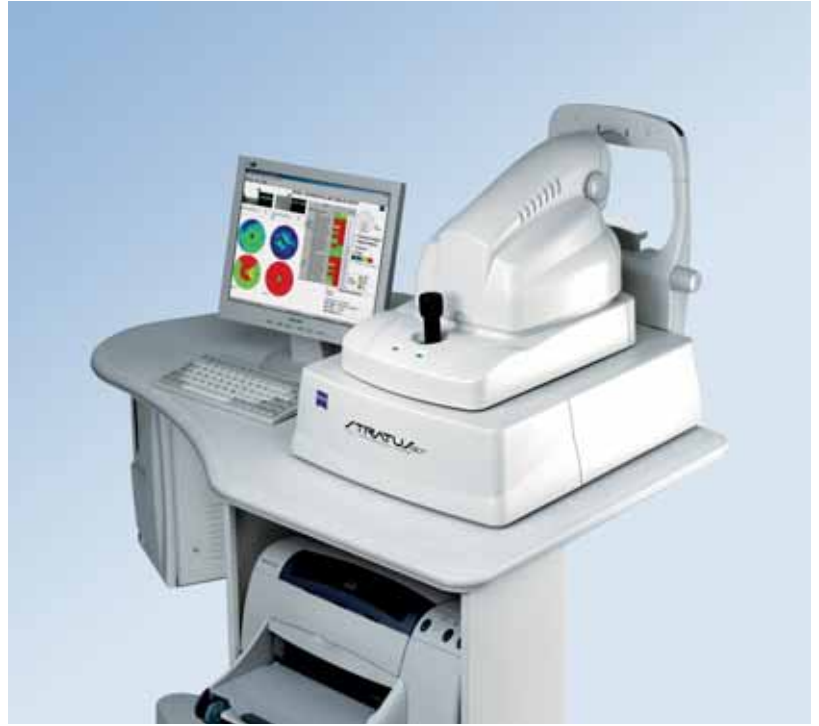Therapy

The method of choice in the area of therapy for diabetic retinopathy is

known as panretinal photocoagulation. This involves the obliteration of peripheral areas of the retina no closer than 2-3 optic disc diameters from the center of the macula by applying more than 1000 coagulation spots of roughly 300-500 µm in diameter. The first mass-produced photocoagulator for the non-invasive thermal destruction of retinal tissue was the Xenon Light Coagulator from Carl Zeiss in 1957. These days, only laser photocoagulators are used.

For dry AMD, which manifests itself in a gradual loss of central vision over many years, there is currently no curative therapy. Attempts are made to reduce the increasing handicap by prescribing low vision devices.

The therapeutic measures in the case of the more dangerous wet AMD are geared toward obliterating



the vessels formed under the macula as a result of choroidal neovascularization (CNV) or toward halting or entirely preventing the formation of new vessels. The vessels are obliterated using photodynamic therapy (PDT). Unlike thermal photocoagulation, this enables the selective destruction of newly formed vessels beneath the fovea without causing any damage to the photosensitive sensory layer above.

PDT used to be the only therapeutic option for decelerating or halting the progressive loss of central vision with wet AMD. Now the first AMD drugs to impede the growth of new abnormal blood vessels are arriving on the market.

Karl-Heinz Donnerhacke, Jena

details

PDT principle

The basic principle behind PDT lies in the triggering of a photochemical reaction in a dye (verteporfin = photosensitizer) under the influence of radiant energy. The products of the reaction (free radicals) then cause the desired damage to the vessels. The dye and radiant energy on their own have no effect. Given that the dye is configured so that it is attracted to the inner walls of the newly formed vessels, these are damaged selectively when laser light is directed onto them.