Visualization of preretinal neovascularization (NV) using widefield swept source optical coherence tomography angiography (SS-OCTA)

Thomas Schlegl, PhD[1,3]; Heiko Stino, MD[2]; Michael Niederleithner, MSc[1,3]; Luis de Sisternes, PhD[3]; Anja Britten, MSc[1,3]; Philipp Matten, MSc[1,3]; Ursula Schmidt-Erfurth, MD[2]; Wolfgang Drexler, PhD[1,3]; Rainer A. Leitgeb, PhD[1,3]; Andreas Pollreisz, MD[2]; Tilman Schmoll, PhD[1,3]

[1] Center for Medical Physics and Biomedical Engineering, Medical University of Vienna, Vienna, Austria; [2] Department of Ophthalmology, Medical University of Vienna, Vienna, Austria; [3] Carl Zeiss Meditec, Inc., Dublin, CA, USA

MEDICAL UNIVERSITY OF VIENNA

ZEISS

Poster #2963 – F0117

PURPOSE

- The occurrence, the corresponding spatial location, and the specific extent of vascular anomalies are accompanying signs of many retinal diseases.
- Neovascularization (NV) located above the vitreoretinal interface indicates proliferative diabetic retinopathy (DR).
- In OCTA en face images, it is often difficult to distinguish whether NVs have penetrated this interface.
- We developed a widefield (WF) SS-OCTA prototype that highlights NVs over a field of view of up to 90 degrees while maintaining Nyquist sampling density.

METHODS

We developed a WF SS-OCTA prototype:

- Scans the retina at an A-scan rate of 1.7 MHz
- Acquisition time at a comfortable 15s

Automated detection of preretinal neovascularization:

- Flattening of the retina via graph-cut-based retinal pigment epithelium (RPE) layer segmentation.
- A deep neural network (DNN) is used for 3D denoising of the OCTA data.
- Specific 3D smoothing filters and morphological operations on the structural OCT data yield a robust internal limiting membrane (ILM) layer segmentation.
- The standard deviation of voxel gray values in the area above the ILM provides the NV segmentation.

Email: thomas.schlegl@meduniwien.ac.at

We acknowledge funding by European Commission H2020 program initiated by the Photonics Public Private Partnership (MOON number 732969).

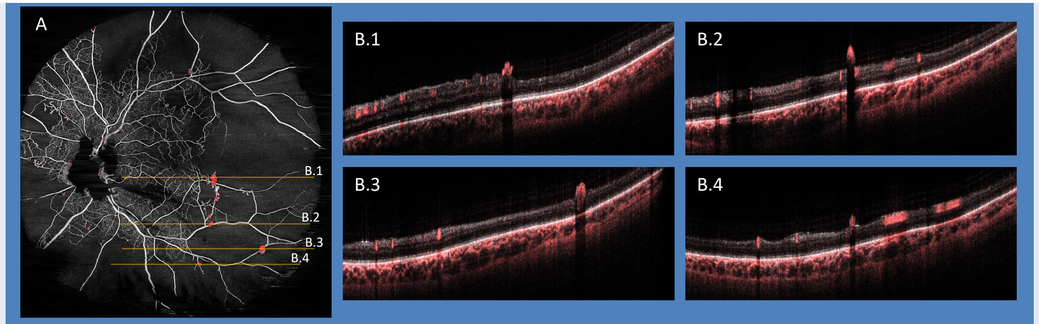

Figure 1. (A) Automated segmentation results of preretinal neovascularizations overlayed on an en face image of a SS-OCTA scan. (B.1-B.4) B-scans extracted from the same SS-OCTA scan at positions of NV occurrences. The yellow lines in (A) indicate the locations of the extracted B-scans. Results suggest that our segmentation algorithm robustly detects locations where the flow signal breaches the ILM.

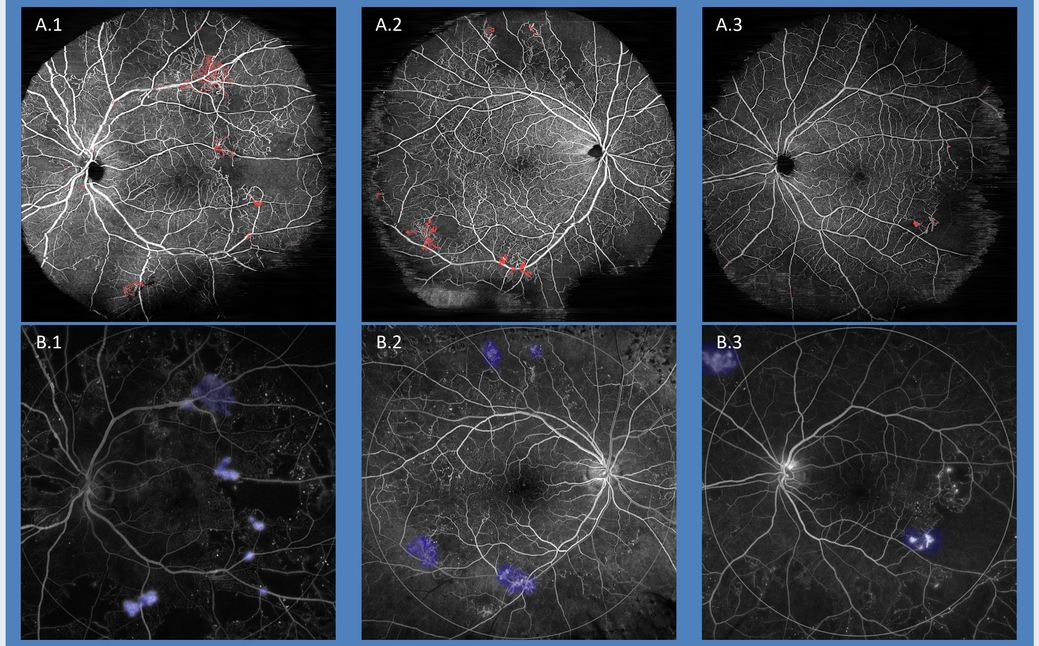

Figure 2. Three eyes of three patients with proliferative diabetic retinopathy. (A.1-A.3) Neovascularization segmentation (red) overlayed on top of SS-OCTA en face images. (B.1-B.3) Fluorescein angiography images of the same eyes with NV annotated (blue) by a retinal expert. The comparison of image pairs (A.1,B.1), (A.2,B.2) and (A.3,B.3) shows that our approach detects all NVs. Mainly in the periphery and near the optic disc few oversegmentations can be identified.

RESULTS

- Our segmentation algorithm is stable in detecting flow signals breaching the ILM (Figure 1).
- SS-OCTA en face images of diabetic patients with overlayed NV segmentation results and corresponding fluorescein angiography images can be seen in Figure 2.
- Our SS-OCTA device produced excellent image quality far out into the periphery.
- With this device, we have so far imaged more than 100 subjects with DR at various disease stages.
- Figure 3 shows a montage of two 18 mm x 18 mm scans of a healthy subject to an ultra-widefield 23 mm x 18 mm SS-OCTA image.

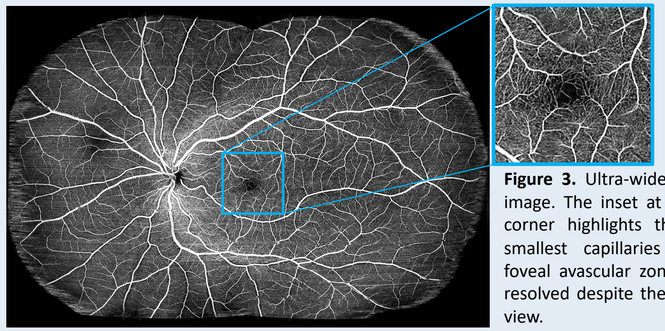

Figure 3. Ultra-widefield SS-OCTA image. The inset at the top right corner highlights that even the smallest capillaries around the foveal avascular zone can still be resolved despite the large field of view.

CONCLUSIONS

- Automated segmentation of NV allows the ophthalmologist to distinguish between proliferative and non-proliferative vascular abnormalities at first glance.
- WF SS-OCTA in combination with DNN-based image quality improvement techniques and segmentation algorithms enhances and simplifies the diagnosis and disease monitoring of preretinal NV.
- In future studies we will aim at demonstrating the benefit of widefield SS-OCTA imaging beyond DR – namely helping doctors tell diseased and healthy subjects at a glance and building more efficient and accurate AI-CDS systems.

Disclosures: ThS (C), MN (C), LdS (E), AB (C), PM (C), WD (C,F), RL (C,F), TiS (E) – Carl Zeiss Meditec, Inc.; HS, USE, AP – None