Dewarping retinal and choroidal thickness maps in widefield optical coherence tomography volumes

Jochen Straub, PhD[1], Areg Noshadi, MS[1,3], Conor Leahy, PhD[1], Jon Bumstead, PhD[1], Arne Ohlendorf, PhD[2], Siegfried Wahl, PhD[2]

[1]Carl Zeiss Meditec, Inc., Dublin, CA, United States; [2]Carl Zeiss Vision GmbH, Aalen, Baden-Württemberg, Germany; [3]Ambu A/S, Munich, Germany

Poster #4088 – F0052

PURPOSE

- Recent developments in optical coherence tomography (OCT) have demonstrated single acquisition widefield imaging with an optical field of view (FOV) of up to 90°.
- The purpose of this study is to evaluate the previously developed OCT volume dewarping and normal incidence method, for the measurement of retinal and choroidal thickness maps in human eyes.

METHODS

Our previous work (*IOVS*, Vol. 61, PB00103, 2020) has demonstrated that dewarping and measuring normal to the retinal pigment epithelium layer is a crucial step when analyzing structure and shape of the retina.

The mathematical model predicted the results to be dependent on the retinal curvature and to increase as a function of FOV.

In this study, we compare retinal and choroidal thickness measurements of 12 healthy right eyes of 12 subjects before and after applying the dewarping and normal incidence method.

For each eye we have acquired 12x12 mm OCT volumes with 3 mm scan depth using PLEX® Elite 9000 (ZEISS, Dublin, CA). Axial eye length is needed for the dewarping algorithm and is measured using IOL Master® 500 (ZEISS, Jena, Germany).

Dewarping and measuring at normal incidence result in thickness maps that are different from measurements along A-scans

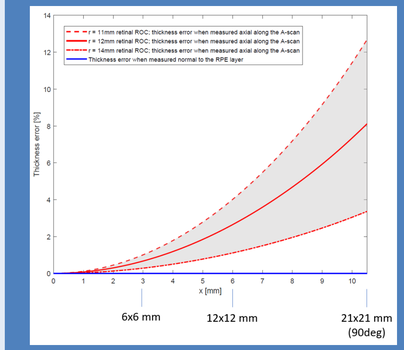

Figure 1: Thickness error in % when measuring axial thickness along an A-scan as compared to measuring normal to a healthy RPE layer. The horizontal axis is the distance x from the center of the scan. The retinal radius of curvature of r = 11 mm to r = 14 x mm represents the range of radius of curvature found in human eyes (Atchison, 2002).

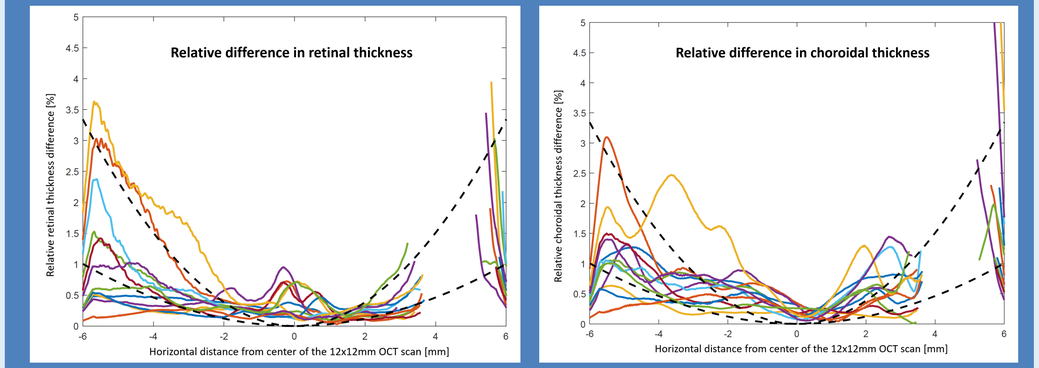

Figure 2: Relative difference in retinal and choroidal thickness measured in 12 healthy human eyes (colored lines) in comparison to the prediction of the mathematical model (dashed black lines). The dashed lines represent the limits of a range of modelled retinal radii (r = 11 mm to r = 14 mm). The gap in data between 3.5 mm and 5.5 mm is caused by the optic nerve head where the retinal and choroidal layers are missing.

Email: jochen.straub@zeiss.com

Disclosures: JS (E), CL (E), JB (E): Carl Zeiss Meditec, Inc.; AN (E): Ambu A/S, Munich, Germany; AO (E), SW (E): Carl Zeiss Vision GmbH, Aalen, Germany.

RESULTS

The traditional way of measuring thickness in OCT volumes is to measure along an A-scan. For small FOV, this method closely resembles the distance between layers normal to the retina pigment epithelium (RPE).

Figure 1 shows the thickness error when measuring thickness along an A-scan instead of measuring normal to the RPE layer.

While the error for a 6x6 mm scan is less than 1%, our data showed that it can reach up 13% for a 21x21mm (90°) FOV in an eye with strong retinal curvature.

The difference varies in magnitude for every individual eye and increases with FOV. Figure 2 shows the results for all 12 human eyes.

CONCLUSIONS

- Dewarping is an important step when analyzing structure and shape of the retina in large FOV OCT.
- Measuring retinal thickness along A-scans introduces an error that increases as a function of FOV angle, reaching up to 13% for a 21x21 mm (90°) FOV scan when compared to measurements normal to the healthy RPE layer.
- The range of differences measured in human eyes matches the mathematical prediction. The results confirm that the magnitude of the difference increases with FOV and is different for every individual eye.