Improved visualization of retinal vasculature using multi-layer segmentation of optical coherence tomography angiographic images

Mary K Durbin, PhD[1]; Homayoun Bagherinia, PhD[1]; Ali Fard , PhD[1]; Torcato Santos, BA[2]; Mário Soares, BA[2]; Catarina Neves, BA[2]; Marta Lopes, BA[2]; Jose G Cunha-Vaz, MD, PhD[2,3]

[1] Carl Zeiss Meditec, Inc., Dublin, CA [2] Assoc. for Innovation and Biomedical Res. on Light and Image, Coimbra, Portugal. [3] Univ of Coimbra, Coimbra, Portugal

Poster #: PB072

PURPOSE

Visualization of vasculature from OCTA is typically done by generating en face angiography images between boundaries of interest segmented from the structural OCT data. The purpose of this study is to qualitatively and quantitatively evaluate a new multilayer segmentation algorithm in comparison to a commercial implementation that segments only the retinal pigment epithelium (RPE) and inner limiting membrane (ILM), and estimates the remaining layers based on predetermined rules.

METHODS

- One eye from each of 34 subjects with early diabetic retinopathy and no edema
- CIRRUS™ HD-OCT 5000 with AngioPlex® OCT Angiography (ZEISS, Dublin, CA)
- 3x3 OCT Angio scan.
- Density of vasculature in angiography en face images was quantified using the commercial method to estimate the percent area of perfused vasculature
- En face angiography images generated using each of two methods:

Figure 1: Superficial and deep en face angiograms, and B-scans showing segmentation, for two segmentation approaches

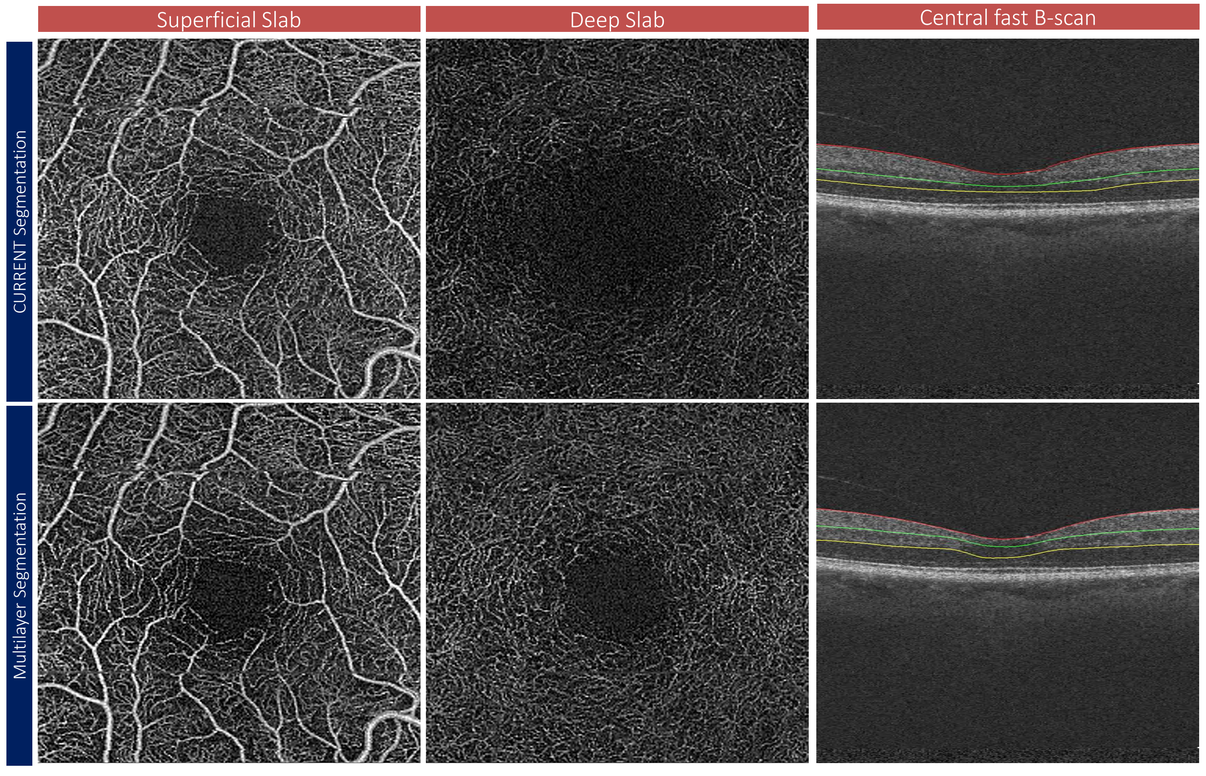

- Agreement between MLS and CS by regression
- Repeatability reported as coefficient of variation (intra-individual standard deviation divided by group mean)

RESULTS

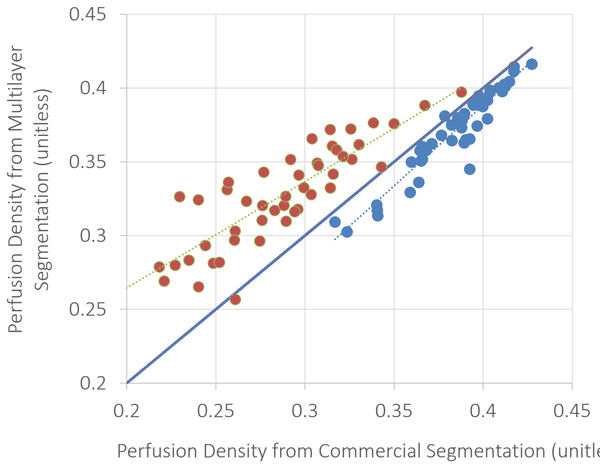

Figure 2: Regression analysis found the two methods were well correlated, with an r-squared of 0.98 for the SRL (slope of 0.99, offset of 0.01, Figure 1, blue) and 0.89 for the DRL (slope of 1.1, offset of 0.01, Figure 1, yellow). As expected, the MLS segmented SRL density was slightly lower than CS while the MLS segmented DRL was higher than with the CS.

Figure 3: Reproducibility of Perfusion Density (left) and Vessel Density (right) in each of four quadrants on 3x3mm scans, using the two methods (Top: Commercial, Bottom: Multilayer) for both the SRL (left grouping in green) and DRL (right grouping in grey).

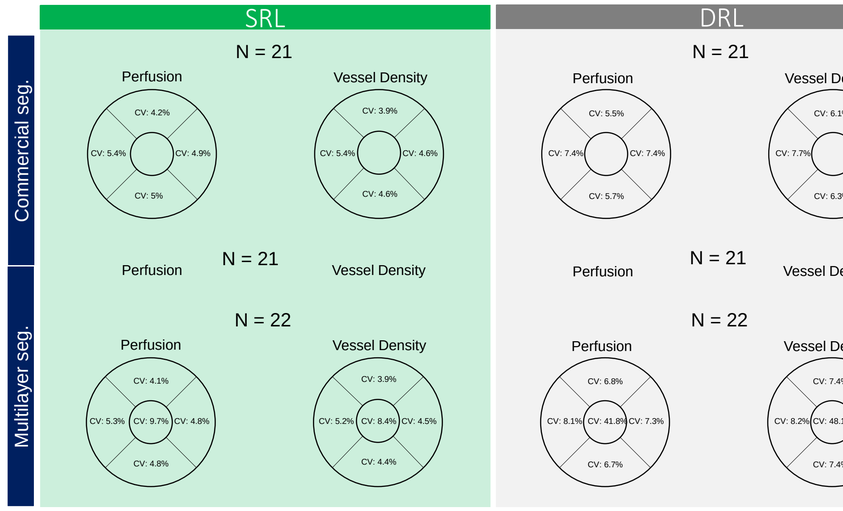

CONCLUSIONS

Multilayer segmentation improves visibility of microvasculature in the deeper retinal layer on OCTA en face images with no cysts. The change affects the quantitative results derived from the angiograms, but the results are correlated to the original results in eyes with early diabetic retinopathy, and the reproducibility remains good.

Email: mary.durbin@zeiss.com

Disclosures: MD (E), HB(E), AF(E), JCV (C), Carl Zeiss Meditec, Inc.; TS, MS, CN, ML (None)