Automatic detection of optic nerve head in widefield OCT using deep learning

Ali Fard, PhD; Homayoun Bagherinia, PhD
Carl Zeiss Meditec Inc, Dublin, CA

Poster # PB0100

PURPOSE

Localization of the optic nerve head (ONH) in OCT and OCTA images is of crucial importance for accurate analysis of the peripapillary region. Automated detection of this landmark is particularly challenging in widefield OCT images of diseased eyes due to the presence of pathologies. Here we present a robust deep learning method for automatic ONH detection in OCT images of healthy and diseased eyes.

METHODS

- OCT en face images were generated from outer boundary of outer plexiform layer to 0.5 mm below retinal pigment epithelium in 1064 structural 6x6mm and 12x12mm OCT volumes acquired using PLEX® Elite 9000 SS-OCT (ZEISS, Dublin, CA).
- ONH center was marked in the images (821 for training and 243 for testing) by human experts.
- OS eyes were flipped along the vertical axis to match the OD eye for training purposes.
- U-net architecture
  - 4 contracting and 4 expansive convolutional layers
  - ReLU activation, max pooling, binary cross entropy loss, sigmoid activation in final layer.
  - 3 input channels: OCT en face image, vessel-enhanced OCT en face image, and OCT contrast map (integral of absolute axial gradient).
  - Target image: 4-mm binary mask shifted by 1mm temporally around the grader-identified ONH center.
- Data augmentation (rotation around the center between -9° and 9° with a step of 3°) was performed to increase the number of training images to 5747.
- The U-net predicted the ONH area followed by a template matching using the 4mm diameter disc. The ONH center is the shifted center position by 1mm in nasal direction .

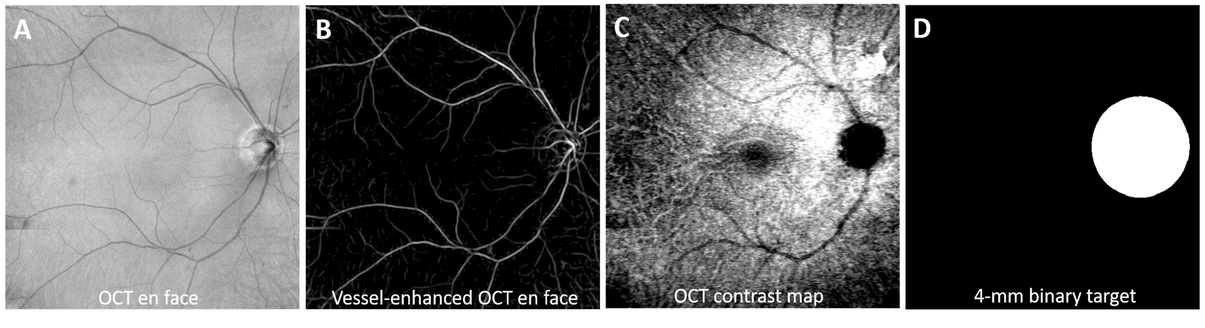

Email: ali.fard@zeiss.com

Disclosures: AF (E), HB (E): Carl Zeiss Meditec, Inc.

RESULTS

- Examples of test images with predicted ONH area, and success rate and histogram plots of the error between the ONH detected by the algorithm and human expert.

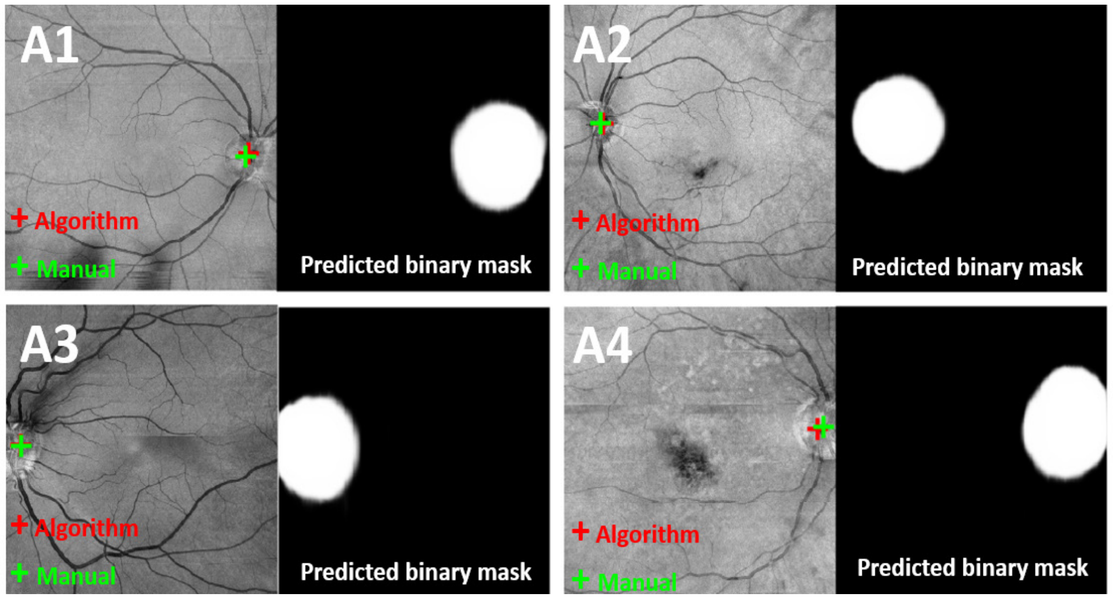

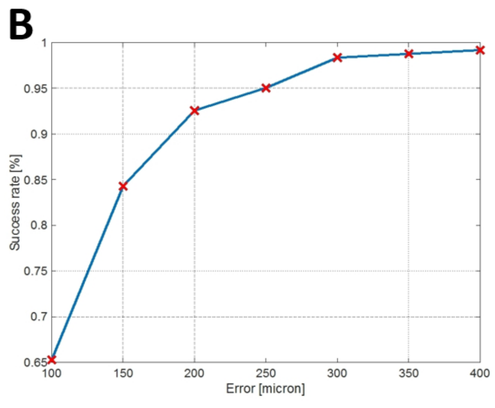

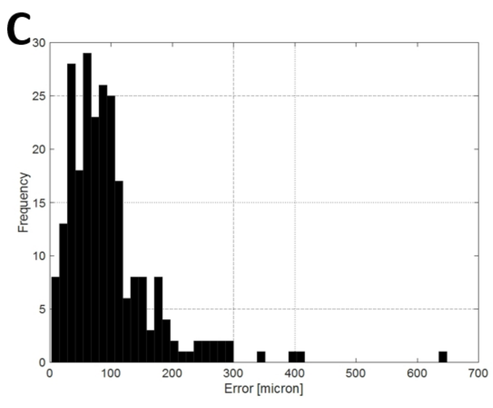

- The algorithm identified the ONH with an accuracy of 300 µm and 250 µm in 98% and 95% of the input images, respectively.
- The mean and standard deviation of the error were found to be 97 µm and 76 µm.

CONCLUSION

Our results suggest that the ONH can be robustly and accurately detected in OCT en face images using a U-net architecture in presence of pathology.