MHz swept-source optical coherence tomography with a 90 degree field of view

Michael Niederleithner, MS[1]; Muzammil Arain, PhD[2]; Hugang Ren, PhD[2]; Rick Williams, PhD[2]; Simon Bello, PhD[2]; Laurin Ginner, MS[1]; Matthias Salas, MS[1]; Jochen Straub, PhD[2]; Wolfgang Drexler, PhD[1]; Rainer Leitgeb, PhD[1]; Tilman Schmoll, PhD[1,2]

[1]Center for Medical Physics and Biomedical Engineering, Medical University of Vienna, Vienna, Austria; [2]Carl Zeiss Meditec, Inc., Dublin, CA

Poster # 1296-A0541

PURPOSE

The field of view (FOV) of commercially available optical coherence tomography (OCT) systems is typically limited to 30 degrees. Images from ultra-wide FOV color fundus cameras have however shown that examining the peripheral regions of the retina may impact the assessment of severity of disease.

METHODS

- Developed a clinical 1060 nm MHz swept-source OCT (SS-OCT) prototype:
  - 1.7 million A-scans per second
  - 93 dB sensitivity
  - 4.5 mW sample power
  - 5 mm imaging depth in tissue
  - 8 µm axial resolution in tissue (FWHM)
  - 14 µm lateral resolution in tissue (FWHM)
  - 90 degree maximum FOV (with add-on lens)
  - Maximum volume size 2048 x 2048 A-scans
- Acquired ultra-wide FOV OCT and OCT angiography volumes of healthy eyes {A - C}
- Extracted virtual B-scans {D} along arbitrary, user selectable traces {blue line in B} throughout the volume.
- Generated virtual HD B-scans {E} by averaging over 20 pixels normal to the selected arbitrary line

ACKNOWLEDGEMENTS

- European Union's Horizon 2020 Research and Innovation Program, MOON, H2020, ICT 732969

Email: tilman.schmoll@zeiss.com

Disclosures: MS (F), MA (E), HR (E), RW (E), SB (E), JS (E), WD (F, C), RL (F, C), and TS (E): Carl Zeiss Meditec, Inc.

RESULTS

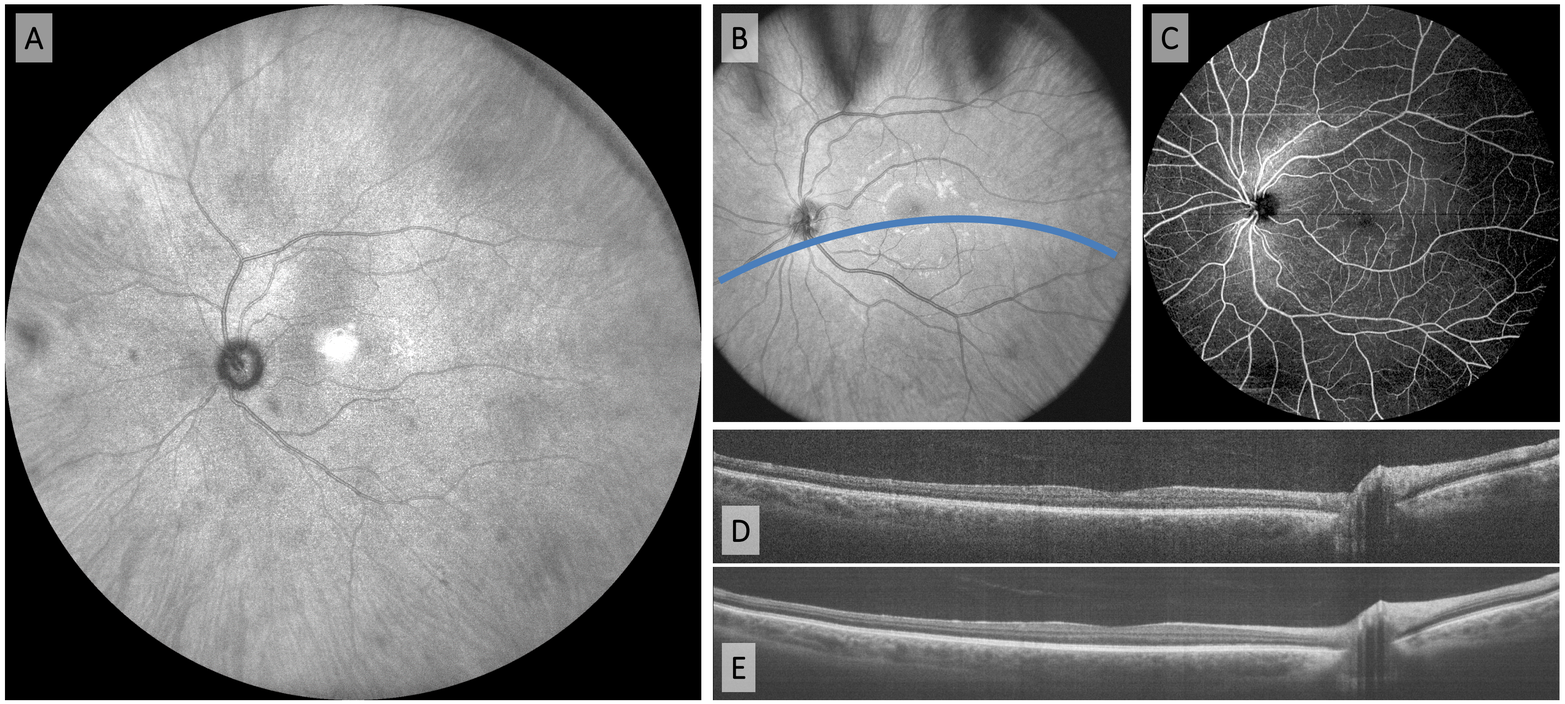

Wide field SS-OCT images of healthy retinas, acquired at 1.7 million A-scans per second:

A. 90 degree FOV enface projection
B. 60 degree FOV enface projection. The blue line indicates the location of the virtual B-scans in {D, E}.
C. 60 degree FOV OCT angiography retina slab
D. Virtual B-scan extracted from a volume acquisition at the user selectable location indicated by the blue line in {B}.
E. 20x averaged virtual B-scan extracted from a volume acquisition at the user selectable location indicated by the blue line in {B}

CONCLUSIONS

The large FOV may provide otherwise hidden diagnostic information and the dense sampling may enable new clinical workflows. After acquisition of just a single comprehensive volume, high quality B-scans may be extracted at arbitrary locations and orientations retrospectively.

References

- Fenner, B. J., et al., "Advances in retinal imaging and applications in diabetic retinopathy screening: a review." Ophthalmology and therapy 7, 2018.
- Klein, T., et al., "Megahertz OCT for ultrawide-field retinal imaging with a 1050 nm Fourier domain mode-locked laser." Opt. Express 19, 2011.
- Kolb, J. P., et al., "Ultra-widefield retinal MHz-OCT imaging with up to 100 degrees viewing angle." Biomed. Opt. Express 6, 2015.
- Blatter, C., et al., "Ultrahigh-speed non-invasive widefield angiography." J. Biomed. Opt. 17, 2012.