Real-time scene understanding in ophthalmic anterior segment OCT images

Hessam Roodaki, MSc [1,2]; Matthias Grimm, MSc [2]; Nassir Navab, Prof. [2,3]; Abouzar Eslami, PhD [1]

[1]Carl Zeiss Meditec, Munich, Germany; [2]Technische Universität München, Munich, Germany; [3]Johns Hopkins University, Baltimore, MD

The first and second authors contributed equally to this work.

Poster # PB095

PURPOSE

- Machine learning algorithms are useful and efficient at interpreting medical images and segmenting anatomies.
- Here we present an approach that goes one step further by gaining **scene understanding** using cutting-edge machine learning techniques.
- Our method reliably **detects anatomies** of the anterior segment of the eye in OCT B-scans and implicitly understands the location of acquisition.

METHODS

- The utilized neural network architecture in our work is **U-net** without fully connected layers, with multiple modifications.
- **Batch renormalization** is introduced to enhance training.
- **Squeeze and excitation** layers are added to improve interdependencies between channels.
- **Dilated convolutions** are also used to increase the receptive field of the network.
- Our design emphasizes on **scene understanding** to accurately learn the correct position of anatomies relative to each other.
- The **ADAM** algorithm is used for training with **cross entropy loss** as cost function.
- The neural network classifies input image pixels as one of **cornea, sclera, iris or background classes**.
- A **spectral domain OCT** system is used for data acquisition.
- An automated method is employed to capture random OCT B-scans with varying parameters such as size, scale, location and gain from ex-vivo porcine eyes as training dataset.
- Anatomy annotation in the acquired dataset is initialized by multiple automated algorithms and then manually refined.

Email: hessam.roodaki@zeiss.com

Disclosures: HR (E), AE (E): Carl Zeiss Meditec AG, MG (N), NN (N)

RESULTS

- In total **7503 training images and 1136 validation images**, captured by a modified Lumera 700 microscope with RESCAN 700 (Zeiss, Oberkochen, Germany), are used.
- The network achieves an **accuracy of 95.62%** pixel classification in all classes and the entire validation dataset.
- Inference on a 1024×1024 pixels OCT B-scan takes about **50 milliseconds**.

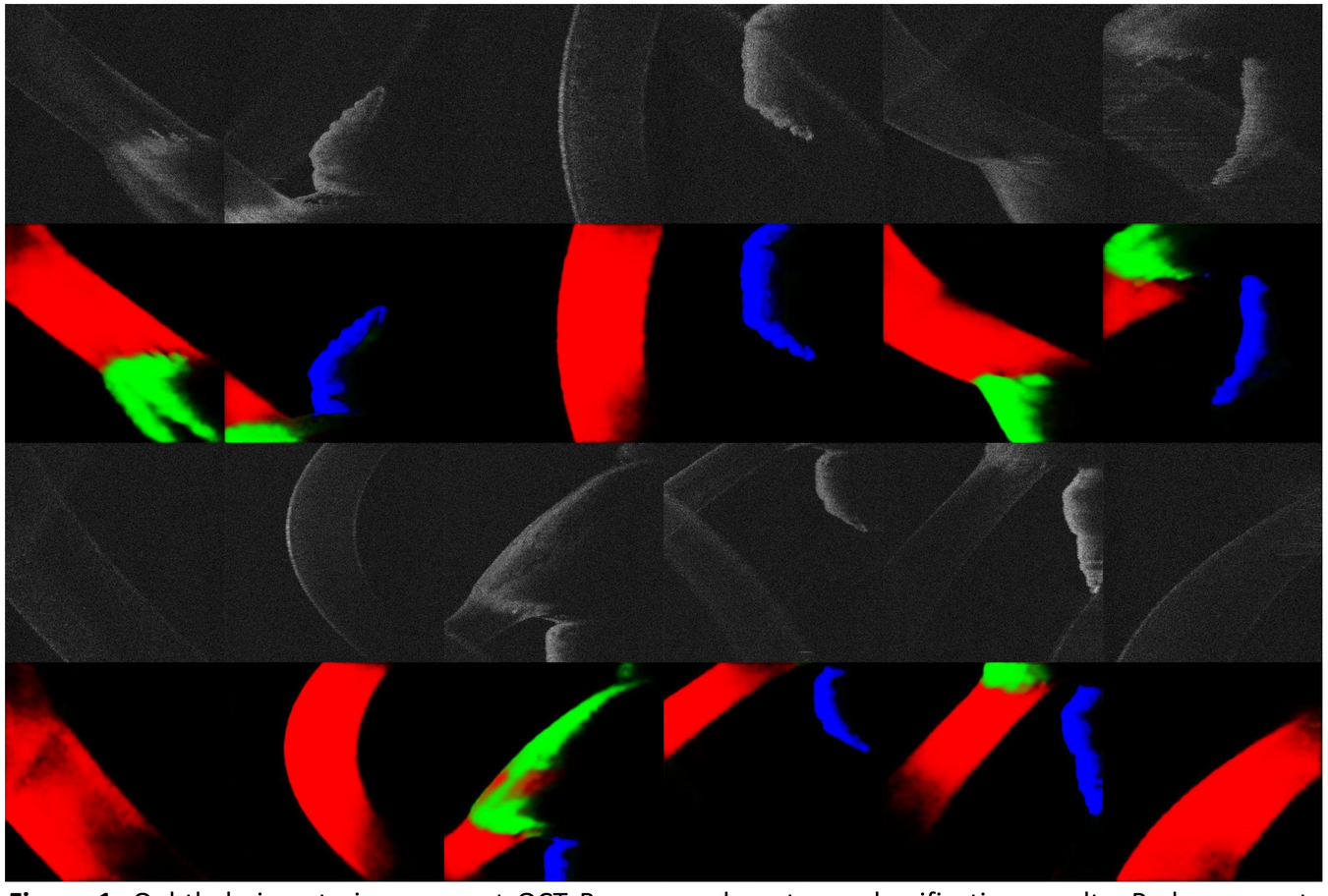

Figure 1. Ophthalmic anterior segment OCT B-scans and anatomy classification results. Red represents cornea, green is sclera, and blue shows iris.

CONCLUSIONS

- We have presented a reliable method using machine learning for **real-time OCT anatomy classification** with acceptable accuracy.
- The algorithm succeeds in segmentation **independent** of the input image size, scale or location.