Deep learning approach to improve the efficiency and effectiveness of optical coherence tomography (OCT) scans

Lingling Wang[1], Jianchun Zhao[2], Xuan Zou[3], Xuan Chen[3], Chunhui Jiang[4], Xing Liu[5], Hui Xiao[5], Yao Zhang[6], Jun Wu[6], DaYong Ding[2], Junfeng Tan[1], Yuan Tian[1], Ningjiang Chen[1]

[1] Carl ZEISS China Innovation and R&D Center, [2] Visionary Intelligence Ltd., [3] Peking Union Medical College Hospital, [4] Eye & Ent Hospital of Fudan University, [5] Zhongshan Ophthalmic Center Sun Yat-sen University, [6] Northwestern Polytechnical University

Poster # 1514 - A0198

PURPOSE

OCT macular exams routinely include a cube scan covering the whole macular region followed by high-resolution scans focusing on critical regions.

1. Scan Preparation → 2. Patient Alignment → 3. Scan Acquisition → 4. Scan Analysis → 5. Report Printing



Fast Cube Scan for Review

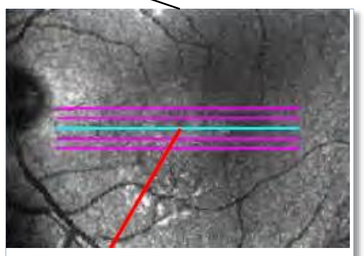

HD Scan for Fine Analysis

This study aimed to develop a deep learning model* to automatically identify pathological anomalies in cube scans, such that the subsequent high-resolution scans can be planned accordingly and automatically.

METHODS

PRIMUS 200 OCT

Carl Zeiss Meditec, Suzhou, China

	Cube (32 images)	HD 5-Line (5 images)	Total B-scan Image
Training set	500	1500	23500
Test set	99	465	5493#
Total	599	1965	28933

Each was annotated by one of three retina specialists with at least 5-year experience

Each was cross-annotated by three retina specialists

* A deep learning model for image quality has also been developed.

\# 369 B-scans were eliminated due to lack of any consensus among annotators.

Email: lingling.wang@zeiss.com

Disclosures: LW(E), JT(E), YT(E), & NC(E): Carl Zeiss Shanghai Co. Ltd. JZ(N), XZ(N), XC(N), CJ(N),XL(N), HX(N), YZ(N), JW(N), DD(N)

RESULTS

Annotation Results & Label distribution

Annotation Category	Training set	Test set	Training classes
No visible anomaly	43%	55%	Normal
Overall deformation	4%	2%	Abnormal
Anomaly across fovea	2%	2%	
Anomaly above ELM	16%	15%	
Anomaly in or below ELM	15%	13%	
Anomaly in sub-retinal area	3%	4%	
Other anomalies	10%	5%	
Unable to determine	7%	4%	

Deep learning model

Original image → Image resize → Data augmentation → Resnet 34 → Classification

Cube: 512x1024
5-line: 1024x1024

512 x 512

Rotation, flip

Sensitivity: 90.8%
Specificity: 90.6%

Confusion matrix

	Normal	Abnormal
Normal	3032	168
Abnormal	307	1617

Heatmap examples (abnormal)

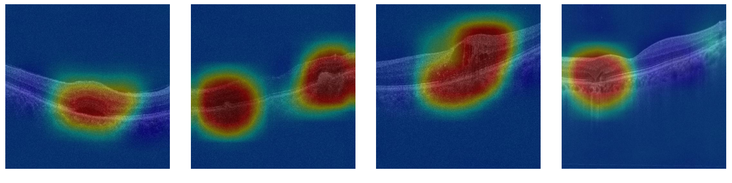

CONCLUSION

It is possible to detect pathological anomalies in OCT with high sensitivity and specificity using a deep learning approach. With this technique being integrated in OCT exam workflow, potential anomalies in a macular cube scan can be automatically identified, making the entire OCT exam workflow more effective and efficient.