Quantification of Optical Coherence Tomography Angiography en face image quality

Charles M Wu, BS; Luis de Sisternes, PhD
Carl Zeiss Meditec, Inc., Dublin, CA

Poster# PB099

PURPOSE

Optical coherence tomography angiography (OCTA) en face scans are subject to artifacts from media opacities, eye movement, and dry eyes that may occur only in parts of the image. This study introduces a method for generating quantitative maps that describe the quality of an OCTA acquisition at each en face location.

METHODS

- OCTA images previously captured on CIRRUS™ HD-OCT 5000 with AngioPlex® OCT Angiography (ZEISS, Dublin, CA) and PLEX® Elite 9000 (ZEISS, Dublin, CA) are graded on a 1-5 scale, 5 being the highest image quality
- A linear machine learning model is trained to recognize the relationship between the Haralick features, a set of texture properties, and assigned quality grades of OCTA images (see Table 1).

Training						
	3x3mm Angio	6x6mm Angio	8x8mm Angio	12x12mm Angio	Total Images	Total Eyes
CIRRUS w AngioPlex	57	56	37	0	150	29
PLEX Elite	378	37	0	37	452	39

Table 1. Data set used in training the machine learning model.

- The model is tested using another set of images to determine the accuracy (see Table 2).

Testing						
	3x3mm Angio	6x6mm Angio	8x8mm Angio	12x12mm Angio	Total Images	Total Eyes
CIRRUS w AngioPlex	52	44	37	0	133	29
PLEX Elite	0	243	0	0	243	49

Table 2. Data set used in testing the accuracy of the machine learning model

- Data is analyzed for mean absolute scaled error (MASE) as well as standard deviation

RESULTS

- The model predicts CIRRUS image quality with a MASE of **0.49 ± 0.37** in the 3x3mm scans, **0.6 ± 0.4** in 6x6 scans, and **0.6 ± 0.41** in 8x8 scans.
  - Overall MASE of the model for CIRRUS data was **0.56 ± 0.3,** representing a relatively accurate forecast of image quality.
- The MASE for the PlexElite was **0.6 ± 0.48**.
- **Good visual correlation** was observed between the generated quality maps and repeated scans from the same eyes with varying quality (Figure 1).

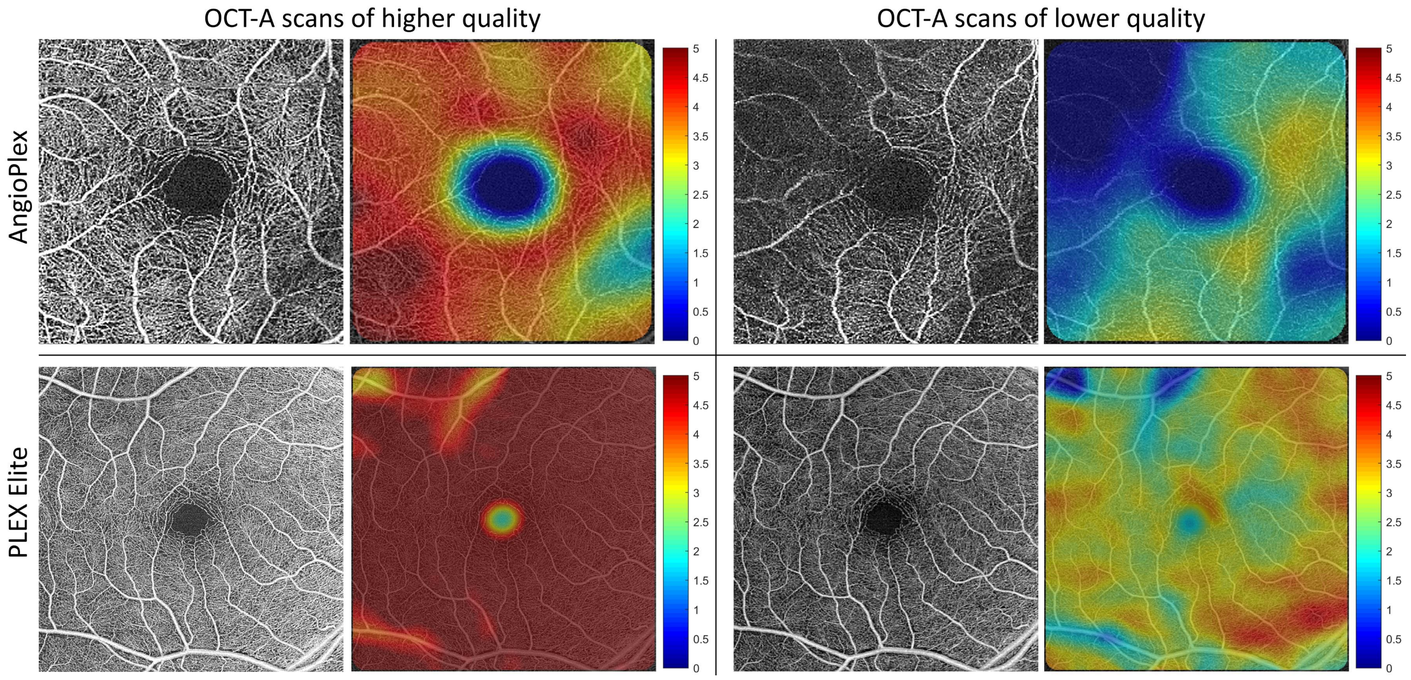

Figure 1. Example of quality maps obtained from repeated scans of the same eyes with varying quality. Top: 3x3mm scans from CIRRUS with AngioPlex. Bottom: 6x6mm scans from PLEX Elite.
Note: Top and Bottom are **different** patients

CONCLUSION

The machine learning model was able to assess the quality of OCTA scans with relative accuracy and produce regional quality maps that correlated well with visual quality of the data. This method may be useful in providing quantitative feedback to operators when acquiring OCTA data, such as prompting the operator to reacquire an image if the quality metric is below a certain threshold.

Email: Charles.wu@zeiss.com

Disclosures: CW(E), LdS(E): Carl Zeiss Meditec, Inc.