

REFRACTIVE LASER JOURNEY

Navigating Laser Vision Correction

GLOSSARY

ReLEx SMILE in the Context of a Patient’s Lifelong Ocular Journey <i>Martin Bechmann MD</i>	1
State of the Art LVC Procedures: Identifying Appropriate Patients <i>Paola Piccinini MD</i>	3
Enhancement Options After SMILE <i>Walter Sekundo MD, PhD</i>	5
Evaluating Corneal Refractive Options for Presbyopic Patients: Efficacy and Patient Satisfaction <i>Jakob Siedlecki MD</i>	8
Fine-tuning Results for Cataract Patients After Previous Refractive Surgery <i>Amir Hamid MD</i>	10





ReLEx SMILE in the Context of a Patient’s Lifelong Ocular Journey

Martin Bechmann MD, Medical Director, SMILE Eyes Clinics, Munich and Trier, Germany

“A man who does not plan long ahead will find trouble at his door.”
Confucius, Chinese philosopher

As refractive surgeons we have a duty of care to our patients to plan treatments that will stand the test of time. This means taking account of the patient’s ocular journey over the course of a lifetime and making provision for the procedures they are likely to require 20, 30 or even 50 years down the road, not just the 24 months that we typically follow them up after their initial surgery. Our choice of procedure for our refractive patients – the majority of whom are myopes – must be suitable for them now as well as for the other procedures still to come over the course of their lifetime.

Our first contact with the refractive patient is usually when they are in their 20s or 30s. Patients at this stage of their life are more adventurous, less prone to plan for the future and their budget may be somewhat limited. For these myopic patients, we can offer laser vision correction in the form of photorefractive keratectomy (PRK), laser-assisted in situ keratomileusis (LASIK), small-incision lenticule extraction (SMILE®) or if suitable a phakic IOL.

In our center we currently perform 70% SMILE, 20% PRK and 10% femtosecond LASIK in LVC procedures. The percentage of SMILE procedures will almost certainly grow with the introduction of a hyperopic solution in the future. We perform ReLEx® SMILE for every patient that is eligible and will only consider femtosecond LASIK or PRK if there is some compelling reason to exclude SMILE, such as hyperopia, myopia minor than -1.5 dioptres¹ or thin and irregular corneas.

Looking at these refractive surgery options in turn, PRK is a safe, economical and well-known technique, but it has downsides including postoperative discomfort and pain for the patient and slow visual rehabilitation. The opportunity for touch-up procedures with PRK exists but they are not perfect, and particularly so in the case of over-correction. With LASIK, we have a tried-and-trusted technique that is very convenient and that offers rapid visual recovery, but we

need to be aware of the risk of ectasia in vulnerable corneas. The enhancement opportunities for LASIK are excellent – but only in the short term, as we shall discuss later.

SMILE ADVANTAGES

As a newer technique of refractive surgery, SMILE offers distinct advantages over its predecessors: it is minimally invasive and does not require a flap, with therefore less incidence of flap-related complications, there is a strong assumption that there is better retention of biomechanical strength², less dry eye, better and faster recovery of corneal sensation, as well as proven predictability, efficacy and safety.

At an early stage of its evolution, SMILE’s uptake was somewhat hampered by the perception that enhancements were not easily achieved with this technique. While it was certainly possible to perform a PRK touch-up after SMILE, the results were not sufficiently impressive to convince many naysayers to make the transition to SMILE. In recent years, however, advances in laser design, software and surgical techniques mean that this roadblock has now been comprehensively cleared.

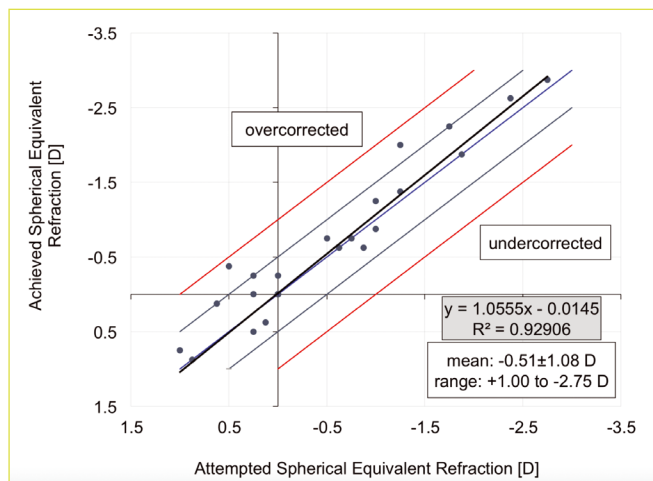
CIRCLE BREAKTHROUGH

The breakthrough came with the development of CIRCLE, a software used specifically with the VisuMax® femtosecond laser (Carl Zeiss Meditec AG, Germany), whereby the laser creates several cuts that convert a SMILE cap into a femtosecond LASIK (femto-LASIK) flap. This means that the flap can be easily lifted using a standard flap-lift technique and the patient can then be enhanced using standard excimer laser ablation.

The safety and efficacy of the CIRCLE technique for enhancement after SMILE was amply demonstrated in recent results published by Jakob Siedlecki MD. Of 2,065 SMILE procedures, 22 eyes were successfully retreated with CIRCLE, with 91% of eyes reported within 0.5D of target refraction compared to 32% before enhancement. The percentage of eyes within ±0.5D of target refraction is according to the spherical equivalent. Safety was also excellent with all eyes gaining at least one line of uncorrected distance visual acuity (UDVA) and no eyes losing more than two lines of vision (BSCVA). In terms of efficacy, this is close to what we would achieve with LASIK in virgin eyes.

The implications of this are quite dramatic when we consider the long-term perspective. If the patient’s first refractive surgery treatment has been SMILE and a retreatment is necessary some 15 or 20 years later, we can easily transfer the SMILE treatment into a femtosecond laser treatment with excellent enhancement possibilities.

This is important bearing in mind the ocular journey that the patient will take over their lifetime. The reality is that we will need these touch-up opportunities in the future because our patients will definitely come back.



CIRCLE enhancement after myopic SMILE®

They typically return to our clinics 15, 20 or 30 years after their initial surgery, except now they will be asking for presbyopic correction.

PRESBYOPIC OPTIONS

We can offer patients in this age group a traditional monovision approach, or perhaps a binocularly optimisation receipt like PRESBYOND® (Carl Zeiss Meditec AG, Germany). However, for different reasons we prefer other solutions than these cornea-based approaches to treat our presbyopic patients. One possible exciting solution on the horizon for these patients is the extended depth of focus phakic IOL, which is currently at an advanced stage of development. If these lenses fulfil their promise, this could really be a game-changer for our presbyopic patients.

A multifocal refractive lens exchange for this age group is not a good option because of the risk of retinal detachment in patients who have previously undergone myopic laser vision correction. This has been shown very clearly in the scientific literature, and in particular a landmark French study of 2.5 million cases where it was shown that age is the most important risk factor for the development of retinal detachment in myopic patients aged 40-to-55.³

●

“We have become much better these days at attaining target refraction thanks to modern power calculation formulas”

●

CATARACT OPTIONS

The third major contact that we will have with our patients comes when they return to us for cataract surgery. These patients are usually over 55, very risk averse and liable to be very demanding about their overall and ocular health. In this age group, refractive surgery equates to lens surgery, with the key decision being whether to opt for a monofocal refractive lens exchange with a monovision approach or multifocal/EDOF IOL implantation.

Lens surgery after previous laser vision correction is demanding because of predictability issues and biometry is definitely more challenging in these cases. Nevertheless, we have become much better these days at attaining target refraction thanks to modern power calculation formulas such as the Haigis-L and tools such as the ASCRS online IOL calculator. We are definitely looking forward to using the TK formula of the IOLMaster® 700 in post-LASIK cases. The measurement of the posterior corneal surface will help us in getting even better results. In our clinic in Munich we are currently undertaking a study in SMILE cases regarding this topic. Despite such advances, there is still a chance that we will need to resort to an enhancement procedure to fine-tune the refractive outcomes. This is where the type of refractive laser surgery that the patient initially underwent plays a role in orienting our choices for current treatment.

If the patient underwent a PRK procedure in their 20s or 30s, we can do a touch-up without any problem but the predictability is comparatively low and it is quite uncomfortable. If the initial technique used was LASIK, we can perform a flap re-lift in order to perform an additional ablation. However, we need to bear in mind that the risk of epithelial ingrowth increases dramatically over time for these LASIK patients.⁴ That is why we prefer not to touch the flap again.

If the patient had undergone SMILE as the primary refractive procedure, we now have an elegant surgical method for enhancement using the CIRCLE software. Using this approach there is no increased risk of epithelial ingrowth and we perform what is essentially a primary LASIK procedure in these eyes.

In my experience, refractive lens exchange with a multifocal implant is not usually a good option for these myopic patients. In our clinic we tend to err on the side of caution and will rule out patients with amblyopia, primary myopia higher than 6 dioptres (because in these high myopic patients the retinal function can be too much altered to give satisfactory results with multifocal IOLs), macular pathology and irregular corneas.

CONCLUSION

Putting all of this into context, SMILE is the current procedure of choice in our clinic as it offers the best touch-up opportunities of all the laser vision correction options over the long term. I believe that this really does herald a paradigm shift in refractive surgery because the CIRCLE enhancement results are so good. There is a popular German saying “Aller guten Dinge sind drei”, which means that all good things come in threes. We can expect our patients to keep coming back to our clinics at least three times for separate interventions over the course of their lifetime. It is our responsibility and duty to be prepared for that and to make adequate provision for their lifelong refractive needs. SMILE helps us to achieve that.

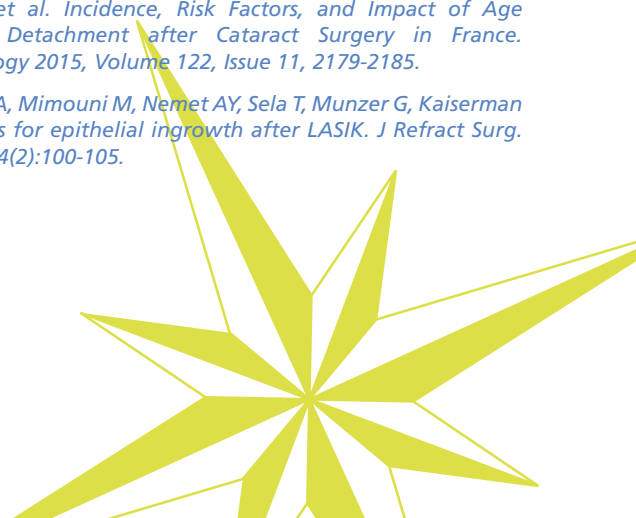REFERENCES

¹ -1.5D is the clinical protocol the author used in his clinic. The CE-approved range for SMILE® is: Sphere: -0.50 to -10.00D; Cylinder: 0 to 5.00 D; Spherical equivalent: -0.50 to -12.50D.

² Sinha Roy A et al, Comparison of biomechanical effects of small-incision lenticule extraction and laser in situ keratomileusis: finite-element analysis. *J Refract Surg.* 2018 Jun 1;34(6):419-423. doi: 10.3928/1081597X-20180402-05.

³ Daien, V. et al. Incidence, Risk Factors, and Impact of Age on Retinal Detachment after Cataract Surgery in France. *Ophthalmology* 2015, Volume 122, Issue 11, 2179-2185.

⁴ Friehtmann A, Mimouni M, Nemet AY, Sela T, Munzer G, Kaiserman I. Risk factors for epithelial ingrowth after LASIK. *J Refract Surg.* 2018 Feb 1;34(2):100-105.





State of the Art LVC Procedures: Identifying Appropriate Patients

Paola Piccinini MD, Centro Oculistico Sardo, Sassari, Italy

In just a few short years, small-incision lenticule extraction (SMILE®) has made the transition from niche surgical curiosity to mainstream technique, with surgeons attracted in increasing numbers to the lure of a minimally invasive intrastromal procedure that delivers LASIK-like results for myopia and myopic astigmatism.

I was immediately attracted by the possibilities of SMILE® when it was first introduced by some of my European colleagues. The concept of a minimally invasive procedure that delivered consistently excellent refractive outcomes and that respected the biomechanical integrity of the cornea was something that was very appealing to me as a refractive surgeon. By focusing the treatment exclusively on the stroma, SMILE preserves Bowman's layer, which is inherently good for biomechanical stability, and, when it is possible to perform the treatment under 130 microns, preserves the superficial nerve plexus.

I liked the fact that SMILE offered a tissue-sparing procedure focused on the stroma, but without all of the inconveniences of PRK such as postoperative pain, discomfort and delayed visual rehabilitation. Up until 2010, the vast majority of my refractive surgery cases had been PRK. Around that time, our clinic decided to invest in the VisuMax® femtosecond laser (Carl Zeiss Meditec AG, Germany) and we soon started performing femtosecond LASIK with very good results.

However, once ReLEx® SMILE (Carl Zeiss Meditec AG, Germany) became commercially available and started to make an impact, we knew that this was the direction that we wanted to take our practice. SMILE seemed to offer all of the advantages of LASIK, but without the downside of a flap and the flap-related complications. We were already familiar with the VisuMax laser, so that definitely shortened the learning curve for us. Nevertheless, it was still an exciting moment for us when we performed our first myopic SMILE procedures in April 2014.

IMPRESSIVE RESULTS

From the outset, we were impressed by the results in terms of the quantity and quality of vision that our patients achieved. While it has often been said that SMILE is technically difficult, this was not really our experience. Although our familiarity with the VisuMax platform clearly helped in this respect, we found that once the basic steps of the procedure had been mastered, the surgery itself was not overly complex and usually proceeded in a smooth and controlled manner. Based on the excellent initial results and the positive feedback of patients, we soon began to offer SMILE as the first-choice procedure to our patients with myopia and myopic astigmatism who expressed an interest in corneal refractive surgery.

Patient selection remains a critical component in achieving postoperative success in refractive surgery, and SMILE is no exception. Many of the requirements for SMILE surgery reflect the standard parameters for other laser refractive techniques, including ocular health, age and refractive

error. In our clinic we consider all patients in the range of -2.0D to -10D and astigmatism up to 5.0D to be potential SMILE candidates' unless there is an obvious reason to exclude them such as thin corneas, irregular astigmatism or topographic data indicative of potential subclinical keratoconus. I prefer to be conservative and always err on the side of caution when it comes to operating on thinner corneas. As we all know, the risk of post-refractive surgery ectasia is a very real one and I see no reason at all to increase the risk even slightly by performing corneal refractive surgery on suspect corneas when there are other alternatives available.

I would estimate that about 40% of our patients undergo SMILE procedures, and that percentage is increasing all the time due to patient demand and expanded indications on the back of multiple robust clinical studies. Like other refractive surgery clinics, we eagerly anticipate being able to offer a hyperopic SMILE solution in the near future, and this will undoubtedly generate even more demand for our services.

●
“The concept of a minimally invasive procedure that delivered consistently excellent refractive outcomes and that respected the biomechanical integrity of the cornea was very appealing”
●

CHAIR TIME KEY TO SUCCESS

When the patient first comes into our clinic we always take time to explain to them all of the corneal refractive options that are available to them. It is important that they fully understand the differences between the various options such as LASIK, PRK and SMILE, and why we believe that a particular procedure will be the appropriate choice for them. Chair time is vital in managing patient expectations and we spend a lot of time discussing patients' wishes and their particular ocular needs in terms of their individual career, lifestyle or hobbies. After all, these patients are typically in the 20-to-40 years of age bracket and these are the most active years of their lives, so we need to be sure that we are offering them the best surgical solution tailored to their own particular situation. There is no “one-size-fits-all” solution for these young refractive patients.

When it comes to discussing SMILE, I explain to the patient that this is a minimally invasive procedure, which does not require a flap, and that they can usually return to normal activities within a day or two of their procedure. This is a very attractive proposition for this younger age group who lead an active lifestyle and who do not want to be incapacitated for several days after surgery or who can

afford to wait a long time on full visual rehabilitation. SMILE frequently appeals to them because it offers the possibility of a rapid return to their normal activities or hobbies, even if those pastimes happen to be boxing or water sports. Patients are also apprehensive about the prospect of postoperative pain or discomfort with surface ablation procedures, so they are usually very relieved when they hear that SMILE offers them a virtually pain-free recovery period.

One of the aspects that has particularly impressed me with this technique is the positive feedback that we get from patients after their SMILE procedures, either directly to us or posted on our clinic's social media pages. Happy patients are the best form of advertisement for any refractive surgery procedure and it is gratifying to see how enthusiastic our patients are in recommending SMILE to other family members and friends. Patients are very pleased with the quality of vision and the fact that the postoperative recovery is so comfortable and that they can return to work usually within one day of their procedure.

Overall, I am very satisfied with the quality of my clinical results with myopic SMILE, which are broadly in line with those reported in the scientific literature. I did make some adjustments to my nomogram after my initial series of patients' experienced slight under-correction, and the refractive outcomes are much tighter now. Perhaps it is down to judicious patient selection, but for the moment I have not had to perform even one enhancement after SMILE. Even those early patients who were slightly

under-corrected for distance vision did not feel that it was sufficiently bothersome to warrant further surgery and they were quite happy overall with the quality of their vision.

CONCLUSION

I experienced a lot of initial scepticism from my colleagues in Italy when I first started performing SMILE, but they are a lot more interested and less sceptical today. What is patently clear to me and most of my colleagues is that SMILE is here to stay. LASIK is a wonderful procedure and will be around for a long time to come, but there is a clear trend towards minimally invasive procedures and the momentum is with SMILE.

We are seeing a lot more results published showing that the safety and efficacy is equal to or better than LASIK and SMILE clearly has the edge in terms of preserving nerve fibres. Taking all this into consideration, I truly believe that SMILE gives us even more treatment options and represents the future of corneal refractive surgery.

REFERENCES

¹ *This is the clinical protocol of the author used in her clinic. The CE-approved range for ReLEx® SMILE® is: Sphere: -0.50 to -10.00D; Cylinder: 0 to 5.00 D; Spherical equivalent: -0.50 to -12.50D.*





Enhancement Options After SMILE

Walter Sekundo MD, PhD, Chairman of the Department of Ophthalmology, Philipps University of Marburg, Germany

With more than 1.5 million procedures worldwide performed by more than 1,300 surgeons in 65 countries, together with a growing and impressive body of evidence in the scientific literature, I think it is safe to say that SMILE® has already established its credentials as a safe, accurate and efficacious refractive surgical procedure. Nevertheless, the reality of refractive surgery is that sometimes enhancements may be required in order to fine-tune the refractive result and give patients the quality of vision that they expected to obtain after their primary procedure.

Although the appeal of minimally invasive refractive laser surgery has encouraged many surgeons to adopt SMILE in their practices, one of the frequently cited drawbacks in the early development of the procedure was the perceived lack of an efficient and safe retreatment method. This is no longer the case. We now have several safe and efficient options to perform enhancements in the rare event of a refractive surprise after SMILE, some of which have been published in the peer-reviewed literature.

CIRCLE

CIRCLE is the official option for ReLEx® SMILE specifically developed by Carl Zeiss Meditec AG, Germany to address the possibility of retreatment after a primary SMILE procedure. This approach uses the VisuMax® femtosecond laser (Carl Zeiss Meditec AG, Germany) to create pre-programmed adjustable circle patterns that enable the original SMILE incision pocket to be converted into a LASIK-like flap. Once the flap has been created, it can then be easily lifted to allow for stromal ablation of the residual refractive error with an excimer laser.

CIRCLE is appealing to many surgeons because it is approved and does not involve any off-label use. It is available within the parameters of the laser software program and is very straightforward to perform. Once the CIRCLE software has prepared the flap, it works just like a primary LASIK procedure.

In a recent prospective, single-center case study series of 27 patients who underwent CIRCLE, successful flap lift was achieved in all cases. The safety outcomes were also excellent with no eyes losing two or more Snellen lines of corrected distance visual acuity and no procedure or flap-related complications or serious adverse events occurring.¹

The principal drawback of this procedure is that the patient is swapping the SMILE cap for a LASIK flap, which entails all of the possible complications of creating the flap. However, it is important to bear in mind that this is not the same as a retreatment after a primary LASIK or femtosecond LASIK procedure. In these cases, the retreatment and re-lifting of the original flap results in a higher risk of epithelial ingrowth and a higher incidence of micro-striae in the flap interface.

When we convert a primary SMILE procedure to a secondary LASIK procedure, however, it is like creating a virgin flap, with a perfect adaptation of the flap edge. This means we experience none of these additional complications such as

epithelial ingrowth, flap microfolds or wrinkles. It is just like performing a primary LASIK procedure, and every surgeon knows that a primary procedure is usually better than a secondary one. From this perspective, CIRCLE offers surgeons a safe, effective and elegant means to satisfy the small percentage of patients that may need enhancement after a primary SMILE procedure.

●

“CIRCLE is appealing to many surgeons because it is approved and does not involve any off-label use”

●

PRK ENHANCEMENT

Advanced surface ablation – PRK/LASEK with mitomycin C (MMC) – offers another safe and viable means of correcting residual refraction after SMILE.

Last year our SMILE EYES group published a retrospective evaluation of 1,963 SMILE procedures in which 43 eyes (2.2%) were re-treated at three separate clinics using surface ablation and intraoperative application of mitomycin C.² The overall results were very good, with the number of patients within ± 0.50 and $\pm 1.00D$ of target refraction increasing from 22.5% and 80% to 72.5% and 92.5%, respectively. Mean uncorrected distance visual acuity (UDVA) improved from 0.23 ± 0.20 to 0.08 ± 0.15 logMAR ($P < .0001$) and 65% of re-treated patients gained at least one line of vision.

We also evaluated four surface ablation profiles available on the MEL 80/MEL 90 excimer lasers (Carl Zeiss Meditec AG, Germany) and found that Triple-A, tissue-saving algorithm and topography-guided profiles all resulted in equally good results, whereas enhancement with the aspherically optimised profile (ASA), used in two eyes, resulted in overcorrection of +1.38D and +1.75D.

It is important to stress that keeping the enhancement procedure flapless is also likely to prove advantageous for the biomechanical properties of the cornea. We have shown this experimentally in a recent study on 96 porcine corneas. The initial refractive correction was defined to be -11.00 dioptres (D) and the required enhancement to be -3.00D. Three different retreatment options were analyzed: -3D Re-SMILE, -3D photorefractive keratectomy (PRK) on top of the SMILE cap and CIRCLE and -3D excimer ablation on the stromal bed (LASIK). The control group did not receive any treatment. The Re-SMILE and PRK enhancement did not significantly reduce the overall elastic modulus of the cornea compared to controls, whereas LASIK enhancement did.³

However, it must be acknowledged that a surface procedure remains a harder sell for some patients despite the advantages it holds for the biomechanical integrity of the cornea. The downside of this particular approach is that it comes with all of the usual inconveniences of surface ablation in terms of postoperative pain and discomfort and requires MMC to avoid haze. In this respect, it stands in strong contrast to SMILE procedures, where patients enjoy a very comfortable, pain-free postoperative period where they can return to normal activities within a few hours of their procedure. Explaining to patients that they will probably experience pain and discomfort for one-to-two days after their surface ablation makes it a far less appealing proposition for many of them.

LASIK ENHANCEMENT⁴

In order to perform LASIK after SMILE, the surgeon needs to have precise and accurate measurements of the cap and ideally excellent OCT-guided visualisation of the original SMILE interface to ensure a safe and effective procedure. The refractive outcomes from this technique are usually very good, as one might expect with modern excimer lasers, but the downside is the fact that we are undermining the tensile strength of the cornea by creating a flap and ablating the cornea with LASIK.

Some surgeons such as Dan Z. Reinstein, one of SMILE's early adopters, advocates a thin-flap LASIK approach for such retreatments. To achieve this, Dr Reinstein creates a cap of at least 135 microns for the primary SMILE procedure, and then plans a 100-micron flap for the LASIK procedure. To ensure that the safety margin is respected, he measures both the epithelial thickness and SMILE cap thickness by optical coherence tomography (OCT) and very high-frequency digital ultrasound, in order to plan the flap thickness to use based on direct measurements.

SUB-CAP LENTICULE EXTRACTION (RE-SMILE)⁴

This is another interesting off-label approach to retreatments after a primary SMILE procedure. The idea was first pioneered by David Donate MD in Lyon, France, and Ahmed Sedky MD in Cairo, Egypt and aims to leave the cap of the primary procedure untouched in order to conserve the benefits associated with SMILE. No new superior lenticule is cut to avoid the risk of a multiple dissection plane. The interface of the primary SMILE procedure then becomes the superior plane of the new lenticule, and the laser is used to create only the inferior plane and side cut of the new lenticule. Once this has been achieved, the surgeon stops the femtolasers cleavage process and the new lenticule is removed through the original corneal incision.

The benefit of this approach is that it does not alter the biomechanical integrity or tensile strength of the cornea. On the debit side, the procedure is technically challenging, requires more tissue removal than needed for the given refractive correction in order to create a new lenticule of reasonable thickness, particularly in small corrections. In addition, we need more clinical studies to establish its safety and efficacy. It is also likely to remain a very marginal procedure by virtue of the fact that it is very rare indeed for primary SMILE procedures to under-correct by

more than 1.0D. With good personalized nomograms, my experience is that regression to such an extent reflects pre-op refraction with a reduced precision, e.g. when the patient did not discontinue his/her contact lens wear for an appropriate time prior to the refraction. As a matter of fact, I expect my patient to discontinue soft contact lenses two weeks and RGP lenses four weeks prior to the refraction appointment. Nevertheless, it is reassuring to know that techniques do exist to perform a secondary SMILE procedure in the event of a substantial correction being required and that good results have been obtained using these methods.

●
“With several options at our disposal, the key to selecting the best retreatment modality depends to a large degree on the personal preference of the patient”
●

FUTURE POSSIBILITIES

Another intriguing possibility on the horizon is the possibility of using corneal collagen cross-linking (CXL) for refractive touch-ups after refractive surgery. The technique, known as PiXL (photorefractive intrastromal cross-linking, Avedro, Inc., USA) uses cross-linking and UV light to alter corneal collagen and thereby induce a refractive change. The specific application of UV-A for each patient takes into account the refractive error and corneal topography.

While it is still very early days, PiXL has shown promising initial visual acuity results up to 12 months. If it delivers on its promise, this may turn out to be an exciting primary treatment for low myopes and a potential game-changer for retreatments after refractive surgery. Here we have a retreatment option where it is not necessary to remove any tissue at all. At the same time, we will be actually strengthening the tensile properties of the cornea by performing cross-linking, effectively killing two birds with one stone. Again, as an Epi-Off procedure PiXL has the same issue as surface ablation. Epi-On treatments are under investigation as of now.

PATIENT COUNSELLING

With several options at our disposal, the key to selecting the best retreatment modality depends to a large degree on the personal preference of the patient. Naturally, we need to consider what is feasible for them taking account of the remaining thickness of the cornea and the magnitude of their initial treatment. I also carefully review the post-op tomography, topography and epithelial maps before offering the solution to the patient. Such factors may lead us to orient their choice one way or another, with safety the overriding consideration. Basically, if all is normal but the RST is limited, the degree of correction is low and/or the patient expresses a strong preference for a flapless

procedure, I will recommend surface ablation with MMC. In the unlikely event of the enhancement needed being over 1.0D, and the patient wants to maintain a no-flap approach, sub-cap lenticule extraction Re-SMILE is the treatment of choice. If the patient insists on a painless procedure, CIRCLE is the way to go, as I routinely use a 120µm cap.

CONCLUSION

Enhancement surgery is an essential and integral part of any refractive surgery practice and SMILE is no different in this respect – the ultimate goal is to deliver the best quality visual results possible for our patients using the latest technology at our disposal and always bearing patient safety and welfare in mind.

The good news for refractive surgeons, however, is that there is every chance that they may not need to perform SMILE enhancements very often. The retreatment rate in our group of 12 specialized SMILE Eyes Clinics is just 2.2%, which is extremely low. With standardized protocols, personal nomogram optimized laser parameters and improved education, there is no reason why other surgeons adopting SMILE won't achieve similarly impressive outcomes.

REFERENCES

¹ Chansue E, et al. Safety and efficacy of VisuMax® circle patterns for flap creation and enhancement following small incision lenticule extraction. *Eye and Vision*. 2015; 2:21. doi:10.1186/s40662-015-0031-5.

² Siedlecki J, Luft N, Kook D, Wertheimer C, Mayer WJ, Bechmann M, Wiltfang R, Priglinger SG, Sekundo W, Dirisamer M. Enhancement After Myopic Small Incision Lenticule Extraction (SMILE®) Using Surface Ablation. *J Refract Surg*. 2017 Aug 1;33(8):513-518. doi: 10.3928/1081597X-20170602

³ Kling S, Spuru B, Hafezi F, Sekundo W. Biomechanical Weakening of Different Re-treatment Options After Small Incision Lenticule Extraction (SMILE). *J Refract Surg*. 2017 Mar 1;33(3):193-198. doi: 10.3928/1081597X-20161221-01.

⁴ Each text is based on the author's own professional opinion or on their study results. It is not necessarily a reflection of the point of view of Carl Zeiss Meditec AG and may not be in line with the clinical evaluation or the intended use of our medical devices. Carl Zeiss Meditec AG therefore recommends that surgeons carefully assess suitability for everyday use in their practice.





Evaluating Corneal Refractive Options for Presbyopic Patients: Efficacy and Patient Satisfaction

Jakob Siedlecki MD, University Eye Hospital LMU Munich, Germany; SMILE Eyes Clinic, Linz, Austria

The surgical treatment of presbyopia remains one of ophthalmology's greatest challenges. As large numbers of baby-boomers reach presbyopic age, the pressure is growing on ophthalmologists to find more compelling solutions for our patients than the traditional prescription for eyeglasses.

While the jury is still out on which surgical approach will ultimately prove the safest and most beneficial in the long-term, there is no shortage of innovative ideas and techniques emerging to address one of the most common refractive side-effects of ageing. In our experience, presbyopic patients are usually well informed and risk-averse: they want a solution that is safe and effective and that will not impact negatively on their quality of life.

For patients with a clear crystalline lens, this group typically do not want to sacrifice the lens, and particularly so if they have had friends or relatives who experienced complications with lens surgery. They often come to our clinic with a specific wish to correct both their presbyopia and ametropia at the same time, or they are simply interested in possible laser treatment of the cornea to correct their refractive errors.

For patients who are experiencing the initial symptoms of presbyopia, usually around the age of 45 or so, we advise them that their presbyopia will increase and that if they have refractive laser corneal treatment it would be prudent to think ahead of the game and introduce some minor monovision to their bilateral refractive equivalent. We do this in order to make sure that they fare well with this modality over the longer term and not just for one or two years postoperatively.

SAFETY MATTERS

When selecting a corneal refractive procedure for presbyopia, safety is the overriding concern that orients the choice of treatment that we offer to our patients. They have many options to choose from including corneal inlays, conductive keratoplasty, multifocal ablation profiles, laser monovision using ReLEx[®] SMILE[®] or advanced monovision protocols in the form of PRESBYOND[®], both from Carl Zeiss Meditec AG, Germany.

Corneal inlays have declined in popularity in recent years due to issues related to the loss of uncorrected distance visual acuity and the requirement to be able to tolerate monovision. The same problem of monovision tolerance is also encountered with conductive keratoplasty, a technique further hampered by variable predictability. We also feel that multifocal ablation profiles have not really delivered on their promise. Despite good predictability, some patients experience loss of corrected distance visual acuity and have difficulty adapting to the inter-ocular rivalry between the two eyes created by this approach.

For these reasons, the choice of corneal refractive surgery in patients with myopia and myopic astigmatism is effectively narrowed down to two options in our clinic: small-incision lenticule extraction (SMILE) monovision, which is a well-

tolerated and effective approach for the correction of presbyopia, or more advanced laser correction using PRESBYOND for those patients who might not tolerate a traditional monovision approach.

There was some suggestion a few years ago that SMILE might not be compatible with monovision. This was based on the notion that the lenticule extraction induces less higher order aberrations (HOAs) than LASIK or PRK¹. The feeling was that while this might be helpful for night vision, spherical aberration is actually beneficial for depth of field and its reduction might thereby hamper the success of SMILE-induced monovision in our presbyopic patients.

The reality, however, as a study we published in 2017² shows very clearly, is that SMILE monovision is a safe and effective option for the correction of presbyopia in myopic patients seeking refractive surgery. The study included 98 eyes of 49 presbyopic patients with a mean age of 49 years seeking surgical correction of myopia or myopic astigmatism who underwent bilateral SMILE[®] monovision procedures.

The target refraction was plano for dominant (distance) eyes and ranged between -0.5D to -1.25D for non-dominant (near) eyes. The distance eyes achieved a spherical equivalent correction of $\pm 0.50D$ from target refraction in 80% of patients and 96% were within $\pm 1.0D$. Binocular uncorrected distance visual acuity (UDVA) of 20/20 or better was achieved in 90% of patients and all patients achieved 20/25 or better. The proportion of patients with a binocular UDVA of 20/20 or better who could read J2 (20/32 Snellen equivalent) or better amounted to 84%. Complete spectacle independence was achieved by 84% of patients and independence from reading glasses was achieved in 92% of cases. No patient requested refractive enhancement or monovision reversal.

THINK STRATEGICALLY

Our strategy is to introduce the degree of monovision according to the patient's age, as we know that regression will happen naturally over time and myopia will increase in the non-dominant eye. Our monovision protocol limits the amount of surgically induced anisometropia to a maximum of 1.25D irrespective of the patient's preoperative binocular near addition. On average, the latter amounted to +1.15D while the mean aimed SE refraction in near eyes was only -0.82D.

Despite this mini-monovision approach, the proportion of patients who could read J1 or better without near addition more than quadrupled to 82% postoperatively compared with preoperative distance-corrected near vision.

The excellent safety profile of the procedure also deserves to be highlighted. No eye lost two or more Snellen lines of corrected distance visual acuity (CDVA). A total of five (10%) of 98 eyes (four distance eyes and one near eye) lost one line of CDVA. Three of them exhibited a preoperative CDVA of 20/12, one had 20/16 and one had 20/20. A total of 63 (62%) eyes experienced no change in CDVA, 27

(28%) gained one line, and 5 eyes (5%) gained two lines. Binocularly, three patients (6%) lost one line of CDVA. Of these, two had a preoperative binocular CDVA of 20/12 and one had 20/16.

To put this in context, our monovision approach has a similar safety regarding the treatment of the respective eye compared to normal SMILE, while avoiding the risks of intraocular surgery². We tell our patients that they must appreciate that there is always some compromise involved between near and distance vision with a monovision approach. Nevertheless, for the vast majority of patients the trade-off is justified in terms of spectacle independence: more than 80% have sufficient visual acuity binocularly for distance and for near vision without having to wear glasses legally for driving, or without having to wear glasses for reading small print.

In terms of spectacle independence, only four out of 49 patients needed to wear glasses for reading or small print after SMILE monovision. In three of these cases, this was an issue of overcorrection of the near eye with a mean deviation from target SE refraction of $+0.50 \pm 0.25D$. For distance spectacle independence, four (8.2%) patients stated that they used distance glasses exclusively for night driving. In three of these, a surgical refractive undercorrection of the distance eye was seen, with deviations from target refraction ranging between -0.75 and $-1.13D$. This underlines the fact that there is no inherent problem with the technique itself, but that it is more a question of not hitting the target refraction in these specific cases.

GETTING BETTER OVER TIME

I think the results will invariably improve as we become more familiar with the procedure. While monovision has been around for a long time, SMILE is still a relatively new procedure to most corneal refractive surgeons. It is not LASIK and we still have much to learn how the corneal tissue is being remodelled after SMILE. My colleague Nikolaus Luft MD has already advanced our understanding of this domain with an interesting study on stromal and epithelial remodelling after SMILE, showing that significant epithelial thickening occurs as a function of the extent of surgical refractive correction. We need to be aware that SMILE causes the cornea to react in a different manner than after LASIK. There is also the absence of the flap to take into account. Once we learn how to interpret all these various parameters, we will be able to produce better algorithms and tighten our refractive results even further.

Patient selection regarding tolerance of monovision and the amount of monovision is very important with SMILE in a presbyopic population.² They need to be over 45 years of age and have a strong desire to be spectacle independent. In our clinic, we estimate that about two-thirds of patients older than 45 have a preference for

monovision. The next step is to correctly identify and correct the dominant eye. In our clinical study, target refraction in the nondominant eye was determined by means of a monovision trial using trial lenses in a trial frame. In regular contact lens wearers, a contact lens monovision trial at home can be conducted additionally, if required. This method is useful to improve patient selection, as has been shown by previous LASIK studies³.

For the estimated 8% to 28% of patients who do not tolerate traditional monovision, PRESBYOND Laser Blended Vision may represent an acceptable and viable alternative. The concept is essentially the enhancement of classic monovision up to 1.5D by adding a proprietary algorithm for a controlled induction of spherical aberrations adding another 1.5D, resulting in a depth of field of up to 3.0D. This creates a "Blend Zone", which improves binocular function in intermediate distances, and makes it easy for the brain to merge the images of both eyes, thereby achieving true binocular vision.

CONCLUSION

The upshot of all these advances is that we can now offer safe and effective solutions to our presbyopic patients. SMILE monovision gives our patients excellent quality of vision and a high rate of spectacle independence. Unlike myopia or hyperopia, presbyopia is a universal problem that affects us all when we reach a certain age. As a corneal refractive surgeon, it is gratifying at last to be able to propose a truly viable solution to an age-old problem.

REFERENCES

- ¹ Gyldenkerne A, Ivarsen A, Hjortdal JO. Comparison of corneal shape changes and aberrations induced by FS-LASIK and SMILE[®] for myopia. *J Refract Surg.* 2015;31(4):223-229.
- ² Luft N, Siedlecki J, Sekundo W, Wertheimer C, Kreutzer TC, Mayer WJ, Priglinger SG, Dirisamer M. Small incision lenticule extraction (SMILE) monovision for presbyopia correction. *Eur J Ophthalmol.* 2018;28(3):287-93.
- ³ Braun EH, Lee J, Steinert RF (2008) Monovision in LASIK. *Ophthalmology*115:1196-1202.





Fine-tuning Results for Cataract Patients After Previous Refractive Surgery

Amir Hamid FRCOphth, Consultant Ophthalmic Surgeon at Optegra Eye Health Care, London, UK

The merging of modern cataract and refractive surgery has created high expectations for today's patients. As surgeons, our chances of achieving successful outcomes in cataract surgery depends upon accurate ocular biometry and IOL power calculations allied to rigorous surgical technique. The process can be particularly challenging for those patients who have previously undergone corneal refractive surgery such as LASIK, PRK or SMILE®.

Although SMILE falls under the broad category of refractive laser surgery, it is important to bear in mind that its impact on corneal tissue is markedly different from LASIK and PRK. This was one of the key features that attracted me to SMILE in the first place: it offers a minimally invasive procedure with a small incision instead of a flap that seems to respect corneal biomechanics¹ and leaves the tear film and ocular surface in much better condition postoperatively than after LASIK. This difference was immediately apparent to me after examining the first few patients on whom I had performed SMILE. I think it is fair to say that the results were even better than expected.

In terms of the speed of visual rehabilitation, it is probably equivalent to LASIK, but there is a strong difference in terms of the level of comfort that patients experience after SMILE compared to post-LASIK. LASIK patients frequently complain about a gritty sensation in their treated eyes in the immediate postoperative period and we often have to give them some topical anaesthesia to take home with them. There are no such issues with our SMILE patients. They leave the clinic almost as if they had undergone no operation at all – they have less trauma, less inflammation and a more comfortable experience overall compared to LASIK patients.

CATARACT CONUNDRUM

When they reach cataract age, these patients who have previously undergone corneal refractive surgery and who are used to having excellent quality of vision are often perplexed when their surgeon warns them that they may have difficulty in achieving consistent, accurate refractive outcomes following cataract removal and intraocular lens implantation. While these patients have a strong interest in restoring or maintaining their relative spectacle independence, the reality is that with current methods and technology we cannot guarantee that they will always hit their target refraction.

There are many variables that affect IOL power calculations, including corneal power, axial length and the effective lens position (ELP) of the IOL after surgery. With eyes that have undergone corneal refractive surgery, it is more difficult to measure the cornea exactly. Although refractive results have improved significantly over time, the large variety of formulas and methods used to assist IOL power calculations tells its own story. The more popular formulas currently in use such as Holladay II, Haigis-L and Barrett True-K work well on virgin eyes but are less accurate on eyes that have undergone a laser vision-correcting procedure in

the past. An exciting development that will be available for use in conjunction with the IOLMaster 700 is the Total Keratometry (TK) function. Early indications are that biometry accuracy is further improved and this will have a significant impact on post laser vision correction patients undergoing cataract surgery.

The good news is that while SMILE affects the cornea in a different way to LASIK or PRK, the principle of IOL power calculation remains the same. We are essentially changing the curvature of the eye and inducing a degree of central flattening to the cornea. The key point to remember is that the relation between the anterior and posterior curvature has been fundamentally altered by the lenticule extraction and it is this modification that introduces the error in lens power calculations. This is the reason that surgeons need to be careful using the established biometry formulas published for LASIK/PRK in eyes that underwent SMILE.

●
“We are essentially changing the curvature of the eye and inducing a degree of central flattening to the cornea”
●

RIGOROUS PROCESS

While hitting the target refraction with an IOL is always going to be challenging after refractive surgery, all of the rules and procedures that we normally apply for virgin eyes are the same for these patients. It is important to ensure that the quality of the process is rigorous from start to finish, that the patient is well prepared, that the ocular surface has not been disturbed and that the patient is fixating properly. For post-refractive surgery patients, I usually perform multiple biometry and topographic readings using at least three different devices and then compare them for consistency. If there is a clear discrepancy, I will conduct repeat measurements and another examination of the tear film and corneal surface.

In our clinic, we use the Equivalent K Reading (EKR) on Pentacam (OCULUS Optikgeräte GmbH, Germany), which draws information from both the anterior and the posterior cornea to generate a range of central corneal power values in keratometric dioptres. This system provides a lot of valuable information about the relation between the respective anterior and posterior surfaces. After SMILE, we typically see very good, consistent keratometry values that are much more regular than after LASIK procedures. This is also apparent when we perform corneal topography on LASIK and SMILE patients. While both groups may have excellent visual results, the topography of post-SMILE patients is much more uniform and regular than for those who underwent LASIK procedures.

METHODS AND PATIENT DEMOGRAPHICS

	EDOF IOL	EDOF IOL post LVC
M-F	1:2	1:2
Age Mean (SD)	57.8+/-6.03	52.5+/-5.15
Age Range	34-74	47-66
Preop SE	0.5+/-1.19	-0.1+/-1.71
Preop Sphere Range	-1.25 to 4.75D	-1.00 to 2.75
Preop Cyl Range	-1.25 to 0	-1.25 to 0
Post Op SE	-0.1+/-0.23	-0.4+/-0.43

- A control group of 50 consecutive refractive lens exchange patients were implanted with an EDOF IOL bilaterally
- 30 Consecutive patients who had previous myopic and hyperopic LVC were implanted with an EDOF IOL bilaterally
- The ASCRS online calculator was used for IOL power calculation and the average power of NO CLINICAL HISTORY FORMULAE USED
- Follow up at one week, two, three and six months
- Monocular & Binocular uncorrected distance, intermediate and near visual acuity were measured
- Dysphotopsia and patient satisfaction was also documented

Post LVC	Myopic LVC	Hyperopic LVC	Total HOA	Coma	Trefoil	Spherical Aberration
30	15	15	0.7+/-0.3	0.3+/-0.2	0.2+/-0.17	0.1+/-0.14

- Post LVC patients had to fulfill the following criteria to be eligible for EDOF IOL implantation
 - No irregular topography/astigmatism
 - No dry eye/ocular surface disease
 - No significant corneal wavefront higher order aberrations
 - No significant negative spherical aberration
 - Sufficient residual stromal bed for laser enhancement should a refractive surprise occur

A particularly useful resource for calculating IOL power in a post-refractive surgery patient is the ASCRS online calculator developed by Warren Hill, MD; Li Wang, MD, PhD; and Doug Koch, MD (<http://iolcalc.ascrs.org/>). To use the calculator, the surgeon selects the appropriate prior refractive surgical procedure and enters the patient data. We try to obtain as much data as possible from the EKR report on the Pentacam, as well as information derived from anterior segment optical coherence tomography (AS-OCT), which provides topographic measurements of anterior and posterior corneal curvatures and corneal thickness. The IOL powers, calculated by a variety of formulas, are displayed at the bottom of the online form, and the surgeon can compare the results to select the best IOL power for the individual situation.

For post-SMILE procedures, we use the option on the online calculator interface for eyes with prior myopic LASIK/PRK and then choose a slightly more powerful lens power than the recommendation. For example, if the average is +25.25D we would typically opt for a +25.50D lens. Most of the time we do not have the luxury of being able to input detailed clinical history data for the patient, so my own personal preference is to use an average of the Haigis-L and Barrett True K formulas incorporated into the online calculator. There is usually a strong agreement between the IOL powers recommended by both of these formulas and we have obtained excellent results using this approach.

EDOF LENSES MORE FORGIVING

The type of IOL that we choose to implant also has an important role to play in delivering optimal outcomes for our post-refractive surgery patients. These patients were typically considered poor candidates for anything other than a standard monofocal lens. However, the latest generation of extended depth of focus (EDOF) lenses may allow us to offer presbyopia correction to our patients as these IOLs do not impact contrast sensitivity in the same way as multifocal optics and are more forgiving of residual sphere or cylinder. I have been using the TECNIS Symphony (AMO Germany GmbH oder Johnson & Johnson Surgical Vision, Inc., USA) and more recently the AT LARA (Carl Zeiss Meditec AG, Germany) lenses in post-refractive surgery patients and the results have been very good. The EDOF lens provides an excellent balance for patients wishing to reduce dependence on spectacles, while inducing fewer visual side-effects than traditional multifocal IOLs.

“The type of IOL that we choose to implant also has an important role to play in delivering optimal outcomes”

Despite all our efforts, some patients will inevitably fall outside 1.0D of target refraction and they need to be warned of this possibility before their cataract removal and IOL implantation. In our hands, the enhancement rate after premium lens surgery in virgin eyes is about 3% to 5%, whereas it is around double that for post-refractive surgery patients using an EDOF lens. We therefore counsel the patient that we can implant an EDOF lens and they will probably obtain a very good result, but there is a higher chance that they may need a laser enhancement afterwards.

Fortunately, if we do need to perform a retreatment after an initial SMILE procedure, the CIRCLE software with the VisuMax® femtosecond laser (Carl Zeiss Meditec AG, Germany) makes life very easy for us in converting the previous cap into a regular femto-LASIK flap. Surgeons need to bear this in mind when they are starting out with SMILE surgery and ensure that they place their incisions at 130-degrees rather than 90-degrees. If they place them at 90-degrees, this will compromise the placement of the hinge for the flap in the event of enhancement surgery and they will be obliged to use a nasal hinge as a result.


CONCLUSION

While we have already made a lot of progress in reducing the possibility of a refractive surprise in our post-refractive surgery cataract patients, there is clearly scope for further improvement in the future. Devices capable of measuring posterior corneal curvature should bring us close to more accurate readings of total corneal power, and technologies such as swept-source OCT, Scheimpflug and intraoperative aberrometry may help us to reduce the margin of error even further.

It is clear that the trend towards minimally invasive vision correction will continue to drive progress in both cataract and refractive fields. As surgeons we have to remain open to trying new procedures in order to bring the benefits of new techniques and technology to our patients without compromising on safety. SMILE has already transformed our refractive surgery practice and is now the treatment of choice for the majority of our myopic patients that are eligible. We hope that very soon a hyperopic SMILE® treatment will be available to enable us to bring the benefits of this technology to even more of our patients.

REFERENCES

¹ *Sinha Roy A et al. Comparison of biomechanical effects of small-incision lenticule extraction and laser in situ keratomileusis: finite-element analysis. J Cataract Refract Surg. 2014 Jun;40(6):971-80. doi: 10.1016/j.jcrs.2013.08.065.*

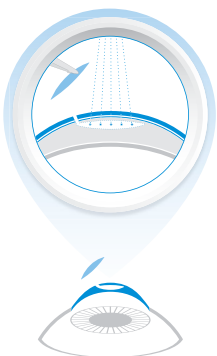


Creating Success with a SMILE.

ZEISS ReLEx SMILE



over 1 million
treated eyes
worldwide



Minimally invasive refractive surgery.

A great smile can be a powerful asset, as everyone knows. It can knock down barriers of doubt, draw people in, create opportunities and set you up for success – much like the minimally invasive treatment procedure SMILE. With over 1 million treated eyes, over 1,300 SMILE surgeons worldwide and with FDA approval in the US, it offers great prospects for success.

www.zeiss.com/smile





Supplement
September 2018

EN_34_021_00521 Printed in Ireland IX/2018

Not all products, services or offers are approved or offered in every market and approved labeling and instructions may vary from one country to another.

CRS-Master, PRESBYOND and MEL 90 are not for sale in the US and/or other countries.

VisuMax, ReLEx, SMILE, MEL, PRESBYOND and CRS-Master are either trademarks or registered trademarks of Carl Zeiss Meditec AG or other companies of the ZEISS Group in Germany and/or other countries.

Each case is based on the author's own professional opinion or on their study results. It is not necessarily a reflection of the point of view of Carl Zeiss Meditec AG and may not be in line with the clinical evaluation or the intended use of our medical devices. ZEISS therefore recommends that you carefully assess suitability for everyday use in your practice.

