

Utilizing Ultra-widefield Swept-Source OCT Angiography for the management of Diabetic Retinopathy.

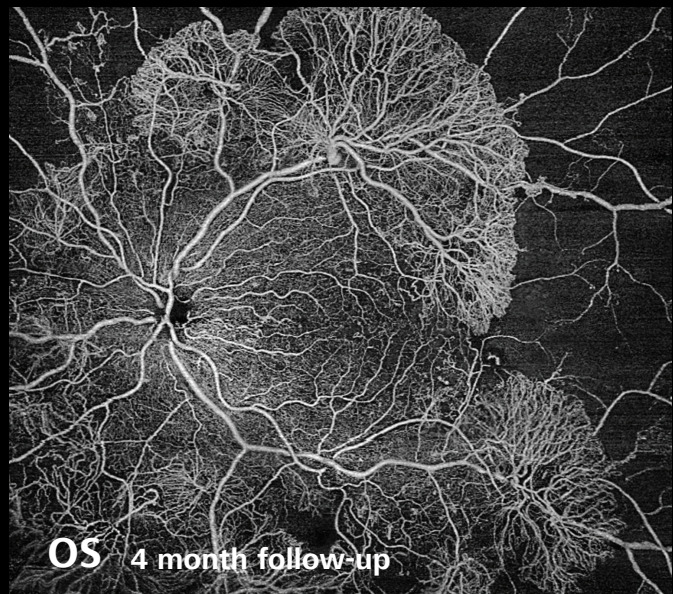
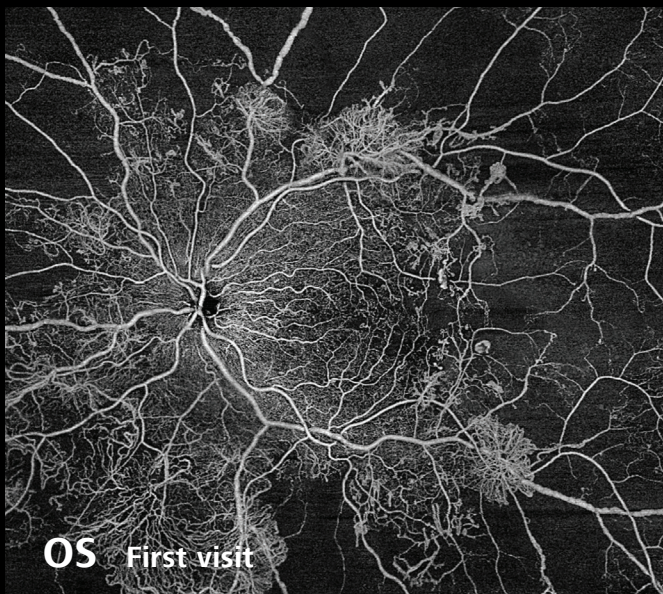
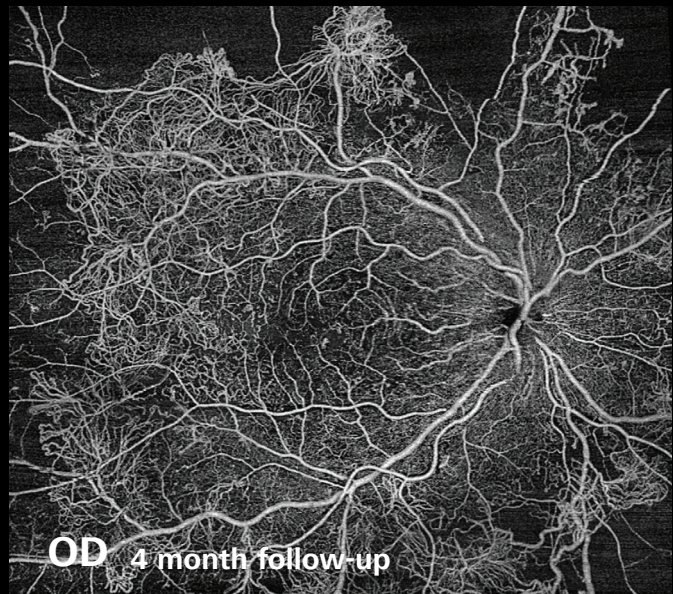
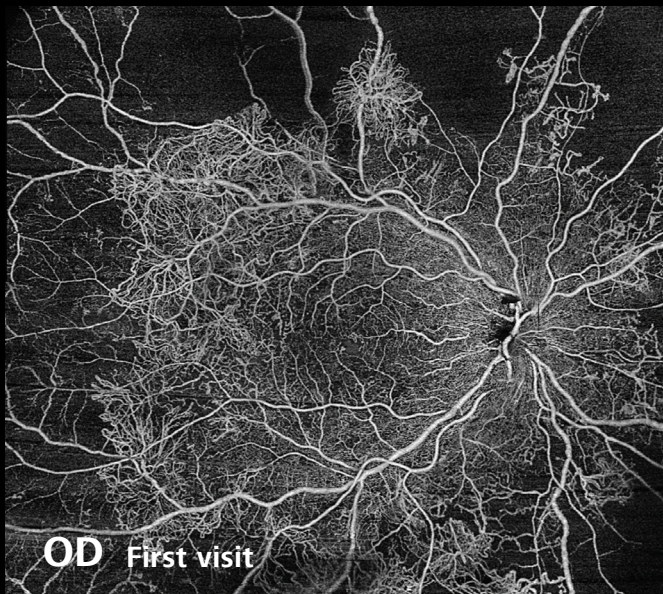


Image & Diagnosis courtesy of Jean-François Korobelnik, University Hospital Pellegrin, Bordeaux, France

BACKGROUND

A young diabetic patient with proliferative diabetic retinopathy.

DIAGNOSIS

Large areas of non-perfusion and significant increases in the proliferation of new vessels are visible between the first visit and 4-month follow-up for both eyes. PLEX® Elite 9000 from ZEISS enables high-speed, widefield imaging with increased scanning depth, ideal for visualizing widespread retinopathy in patients with advanced disease.

