Supplement to

September 2019

Sponsored by Carl Zeiss Meditec

CRST EUROPE

Cataract & Refractive Surgery Today

SMILE

12 YEARS OF LEADING INNOVATION

TABLE OF CONTENTS

Plenty of Reasons to SMILE

The story of this procedure is really only just beginning.

BY MARCUS BLUM, MD

In 2006, Walter Sekundo, MD, PhD, and I presented, for the first time worldwide at the American Academy of Ophthalmology meeting in Las Vegas, our vision of a refractive surgery procedure that could be performed intrastromally using a femtosecond laser and without ablating the cornea.[1] The responses to our presentation ranged from polite interest to skepticism and even ridicule. "It will never work," seemed to be the general consensus.

Nearly 14 years later and after more than 2 million Small Incision Lenticule Extractions with SMILE performed with the VisuMax femtosecond laser (Carl Zeiss Meditec), it is clear that the critics were wrong. Not only does the procedure work—and work very well—but it continues to gain market share as more surgeons discover the benefits of minimally invasive, flap-free refractive surgery for their patients.

THE EVOLUTION OF SMILE

We published our first results with the refractive lenticule extraction procedure for the treatment of myopia and myopic astigmatism in 2008.[2] Taking advantage of the properties of the VisuMax femtosecond laser, during the procedure, a lenticule was manually removed after lifting a corneal flap. Evolving from that early success was the refined option of SMILE. In SMILE, the lenticule interface can be separated through one or two small incisions, thereby eliminating the need for a flap.

The ability to avoid the need for a corneal flap, and therefore eliminate all of its associated complications, is one of SMILE's biggest selling points and one of the reasons the procedure has become so popular. Patients like the idea of minimally invasive intrastromal surgery that can correct their refractive errors and give them excellent quality and quantity of vision.

As the procedure became more popular, the data has accumulated, attesting to the safety and efficacy of SMILE for myopia.[3-6] Our own group recently reported the 10-year results of the first cohort of patients treated by VisuMax, and the results are excellent.[7] In that study, 56 eyes of 30 patients treated in the initial 2006–2007 study were evaluated after 1 decade. Between baseline and 6 months postoperative, no significant changes were found in terms of visual acuity. The mean spherical equivalent at 6 months postoperative was -0.35 ±0.66 D, which was close to target refraction. Further, 16 eyes (29%) gained 1 to 2 Snellen lines. There was no loss of 2 or more lines in the long-term, and regression over the decade since the procedure was minimal.

This long-term study confirmed my own clinical impression that SMILE is effective, stable, and safe for the treatment of myopia and myopic astigmatism.

NEW FRONTIERS

As clinicians continue to become more familiar and confident with the technology, SMILE is opening new frontiers into hyperopia, presbyopia, and keratoconus treatments. Some of these exciting developments, and the possibilities they hold to improve the quality of life of our patients, are presented in the pages of this supplement.

SMILE has come a long way since the early results were first presented in Las Vegas in 2006—it is now an established procedure in the ophthalmological mainstream, and it is gratifying to see so many symposia and scientific sessions at the major meetings devoted exclusively to Small Incision Lenticule Extraction. Thanks to the hundreds of clinicians and researchers who have embraced this technology, it is clear that the SMILE story is really only just beginning. ■

1. Blum M. Clinical case studies with the femtosecond system of Carl Zeiss Meditec. Paper presented at: the American Academy of Ophthalmology Annual Meeting; November 12, 2006; Las Vegas.
2. Sekundo W, Kunert K, Russmann C, et al. First efficacy and safety study of femtosecond lenticule extraction for the correction of myopia: six-month results. *J Cataract Refract Surg.* 2008;34(9):1513-1520. Erratum in: J Cataract Refract Surg. 2008;34(11):1819.
3. Blum M, Täubig K, Gruhn C, Sekundo W, Kunert KS. Five-year results of Small Incision Lenticule Extraction (ReLEx SMILE). *Br J Ophthalmol.* 2016;100(9):1192-1195.
4. Blum M, Flach A, Kunert KS, Sekundo W. Five-year results of refractive lenticule extraction. *J Cataract Refract Surg.* 2014;40(9):1425-1429.
5. Sánchez-González JM, Alonso-Aliste F. Visual and refractive outcomes of 100 small incision lenticule extractions (SMILE) in moderate and high myopia: a 24-month follow-up study. *Graefes Arch Clin Exp Ophthalmol.* 2019;257(7):1561-1567.
6. Agca A, Tülü B, Yasa D, Yıldırım Y, Yıldız BK, Demirok A. Long-term (5 years) follow-up of small-incision lenticule extraction in mild-to-moderate myopia. *J Cataract Refract Surg.* 2019;45(4):421-426.
7. Blum M. et al: 10-year results of SMILE, under review.

MARCUS BLUM, MD
- Chairman of Ophthalmology, Helios Klinikum Erfurt, Erfurt, Germany
- marcus.blum@helios-gesundheit.de

- Financial disclosure: Scientific advisory board (Carl Zeiss Meditec)

The Journey From Critic to Believer

After 4 years of clinical experience with SMILE, I now believe that this procedure will eventually dominate the market.

BY JARNO YLITALO, MD, FEBO

I started performing Small Incision Lenticule Extraction in my clinic in 2015. I had been performing flap-based refractive surgery for just under a decade at that time, but the demand for SMILE came from the public. I was completely happy with my flap-based practice, and I was a little skeptical about the benefits of SMILE, but refractive surgery patients are well informed in Finland and interested in minimally invasive techniques. What was happening in our profession in 2015 was part of a wider trend in medicine, and I understood that the move to minimally invasive, endoscopic surgery represented a logical next step in refractive surgery as it did in every other field of surgery.

Now after careful clinical evaluation over the past 4 years, I am in the position to summarize my experience with SMILE and the VisuMax femtosecond laser technology (Carl Zeiss Meditec) used to perform the procedure (Figure 1).

In my practice, roughly 60% of patients presenting for refractive surgery undergo SMILE, and the rest are treated with femtosecond LASIK (femto-LASIK). At the moment, the standard cap thickness for my SMILE procedures is between 100 and 135 µm, and the flap thickness for femto-LASIK is between 90 and 90 µm. Corneas thicker than 580 µm get a flap of more than 100 µm. For the first time in my clinical work, I am fully happy with the capacities of the technology available to us. In our clinic, we use the VisuMax femtosecond laser for SMILE and the MEL 90 excimer laser (Carl Zeiss Meditec) for femto-LASIK.

PATIENT SELECTION AND PERSONAL NOMOGRAMS

My interest over the past 4 years has been to identify what patients would benefit most from SMILE and what patients would be more suitable for an open-flap procedure.

For the most part, anterior corneal shape determines if a patient is suitable for SMILE. It is good to have symmetrically shaped corneas, with minimal difference between the astigmatic poles. It is also important that the corneal apex is located quite centrally. This makes positioning of the lenticule on the visual axis easier. Therefore, my current indications for SMILE are relatively young patients who have fairly symmetrical corneas; this represents the majority of clients coming to our clinic. On the other hand, patients with corneal astigmatism greater than 3.00 D and older patients are generally better candidates for a flap-based treatment like femto-LASIK.

Figure 1. The VisuMax femtosecond laser.

If the cornea is very asymmetric, the first lens touch in the central cornea may dislocate the position of the lenticule. In these cases, femto-LASIK is preferable, although in my experience SMILE is more tolerant to fluctuations in positioning than excimer ablation. In both cases, it is important to track the position of the optical axis with topography maps because patients might not always properly fixate their sight on the alignment beam.

The SMILE nomogram can be refined over time by the surgeon together with a ZEISS regional clinical application specialist. Initially SMILE technology tends toward slight undercorrection, so it is important to have personal hands-on refraction data both pre- and postoperatively in order to be able to hit the sweet spot of optimal results.

OPTIMIZING THE ENERGY

Energy offset is an important topic. In early experience with SMILE, it is ok to use higher energy input to ensure smooth extraction of the lenticule. In reality, the VisuMax femtosecond laser rarely leaves adhesions between the lenticule and the cornea if the interface between the lens and the cornea is clear. Lowering the energy offset to the optimal level is best done with a ZEISS expert, but finer adjustments of energy offset can be done independently.

In my clinical experience, the best performance of the laser is obtained with a certain geometrical pattern in the cut. Although

the appearance of black spots on the cornea is usually considered a complication of SMILE, a few visible at the cut site is nothing to worry about; it indicates that the energy offset is approaching the critical threshold level.

It is important to keep in mind that the less energy used in creating the lenticule, the quicker the visual rehabilitation will be. Most often, patients leave the clinic on the day of the procedure with binocular vision between 0.7 and 1.0, and the next day they have 1.0 to 1.2 monocular vision with clear corneas if the energy level during the procedure was right. The incidence of haze is a sign that energy levels were too high during the cut.

It is rare to see a prolonged dry eye episode in SMILE patients. Therefore, I always recommend SMILE in patients with signs of transient dry eye symptoms.

FUTURE TRENDS

In the future, I anticipate a continued drive toward even better optical outcomes, as has always been the case in refractive surgery. The next step is that we probably will start routinely concentrating on higher-order aberrations, particularly coma levels. I currently measure coma levels in every patient after surgery, and these results indicate that SMILE is better tolerant of coma compared to femto-LASIK. The most likely explanation is that, during lenticule formation, the eye does not move in relation to the laser beam. On the other hand, during an excimer laser ablation, the eye tracker fixes the ablation beam according to pupillary borders through the corneal tissue. When an eye moves slightly during the ablation, the location of the ablation on the cornea deviates from the planned treatment, as the surface of ablation is not on the same plane as the pupil. For that reason, I perform high myopia excimer ablations in two to three sequences, and it seems to help lower postoperative coma levels in highly myopic eyes.

I have also encountered postoperative coma with SMILE, usually if the interface is not carefully docked and does not take into account patient fixation and the location of the optical axis on topographical maps. The difference, however, is that the presence of coma is usually not a clinically significant phenomenon in SMILE. For that reason, I think the technique is more forgiving in regards to coma.

In order to achieve premium results, we must keep our lenses clear—metaphorically and literally. As professionals, we know the importance of defining the quality of our outcomes, but even patient satisfaction does not tell the whole story about quality. Making the effort to dig down into the details of postoperative residual refraction and use it to improve personal nomograms will lead to increased precision and benefit our future patients.

Achieving an excellent result always comes from a combination of surgical skill, thinking outside the box, and the performance of the laser technology. Very often, we tend to blame complications on the machine and explain to the patient that complications just happen. My view is that using ZEISS technology in recent years has heightened my clinical career. Now I know that when a complication happens, it likely originated from my thinking process rather than the limitations of the technology. This sense of trust and confidence in the ZEISS technology is the best gift that a surgeon could possibly ask for.

CONCLUSION

Laser vision correction technology is always advancing. There will continue to be a place for open-flap LASIK surgery, but I believe that SMILE will take over the market in time. A flapless procedure like SMILE has become the preferred choice for my clients in Finland, and to work in my country without this technology would be demanding. We await the availability of hyperopic SMILE, and this will be a welcomed addition to our refractive surgery practice. I believe that SMILE represents the future of laser vision correction elsewhere, as it delivers a minimally invasive approach with high-quality results in healthy eyes. ■

JARNO YLITALO, MD, FEBO
- Eye Hospital of Silmäasema, Helsinki, Finland
- jarno.ylitalo@silmaasema.fi
- Financial disclosure: None acknowledged

Changing the Paradigm of the Laser Vision Correction Market

The learning curve in SMILE is short, and the demand for it is growing.

BY DANIEL KOOK, MD

In just a few short years, Small Incision Lenticule Extraction has come full circle, from a surgical novelty practiced by a minority of surgeons to a mainstream technique adopted by the wider ophthalmic profession. I started performing SMILE in 2014, when I was the head of the refractive department at the University in Munich. However, it was only when I switched to private practice that I started to perform a much higher volume of Small Incision Lenticule Extractions. After the initial learning curve, I became more familiar with the nuances of the procedure and was in a position to truly offer my patients the most common kinds of laser vision correction: surface ablation, LASIK, and SMILE.

A lot has been written and said about the learning curve with SMILE. Speaking to colleagues and reading the scientific literature, I learned that the learning curve is different for SMILE than it is for LASIK and surface ablation techniques. At the university clinic, I performed keratoplasty procedures, including Descemet membrane endothelial keratoplasty (DMEK). My experience with corneal surgery helped a lot when I first started with SMILE, and it helped to shorten the learning curve. I was also fortunate to be able to call on the expertise of experienced colleagues, who could advise on pitfalls to avoid and also share useful techniques to ensure optimal results.

COMPLICATIONS AND BENEFITS

Taking into account surgical experience, all types of laser vision correction surgery are safe, as long as the indications and contraindications of each procedure are respected. Nevertheless, there are key differences between the procedures.

From my perspective, one of the principal benefits of SMILE is that it induces less dry eye than LASIK.[1,2] Many patients have some degree of dry eye after refractive surgery, which usually resolves spontaneously and at varying times depending on the individual patient and the chosen procedure. For patients aged around 40 who present with dry eye, I recommend SMILE rather than LASIK if there are no other contraindications.

I try not to systemically recommend the same procedure for every patient. Rather, I spend a lot of time getting to know each patient, devising an individualized treatment plan and taking in account his or her particular needs and expectations. It might be surface ablation, or there may be some reason why LASIK is not suitable.

From my perspective, there is not one best technique for every situation, and there is no "one size fits all" approach to refractive surgery. We have more than 30 years of experience with LASIK and PRK, and both continue to be excellent options depending on the specific needs of our patients and their anatomical characteristics.

For younger patients with myopia, low astigmatism, and a normal cornea, I usually propose SMILE; for a patient with high astigmatism or irregular corneal topography, femto-LASIK would probably be a better option. The bottom line is that refractive surgeons are in a position to provide a truly customized approach with the excellent surgical techniques available today.

In terms of contraindications for SMILE, it is important to closely assess the anatomical structure of the cornea. If the patient has a steep but otherwise healthy cornea, there is a slight risk that the surgeon may run into problems with the laser cone during the docking phase of the procedure (Figure 1). In this instance, the patient should be warned of the possibility that the procedure must be aborted and a surface ablation performed a week later. If he or she accepts that risk, then I will proceed with SMILE. When the patient has given consent and has been fully informed, he or she can more readily accept a conversion to surface ablation if required.

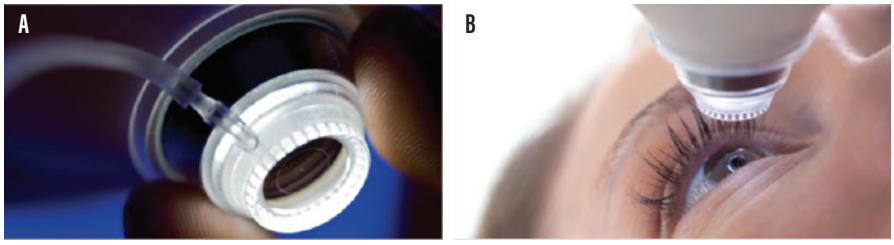

Figure 1. The contact glass on the VisuMax (A) is designed to fit the anatomy of the eye (B). As a result, the cornea largely retains its natural physiological shape.

CHANGING LASER VISION CORRECTION MARKET

The demand for refractive surgery has been fairly stable over the past decade. In Germany,

an estimated 100,000 to 110,000 eyes undergo refractive surgery every year.[3] Like a lot of other European countries, however, the laser vision correction market in Germany is currently undergoing a slow but progressive transformation due to demographic factors and the availability of new technology and surgical techniques. First, the market for presbyopic correction is growing in Germany. This is no surprise: Of the total German population (approximately 80 million), 24.1 million are between the ages of 40 and 59, and this the largest age group in Germany. Although the rise in myopia in Germany aligns with global trends in developed countries, the change in the population profile means that fewer young people are seeking laser vision correction to treat their refractive errors. The result is that a lot of clinics that offer LASIK are experiencing less demand because of the population change.

By contrast, we are seeing strong growth and demand for minimally invasive surgery, and more patients are coming to the clinic asking for it. An estimated 60,000 eyes are treated by femtosecond laser annually, and SMILE's current market share is about 33% and increasing every year. Our patients today are better informed. They understand the principle behind lenticule removal (Figure 2) and the potential benefits that minimally invasive surgery offers. They like the idea of not having a flap with less risk for dry eye. It seems probable that SMILE will gain further market share once treatments for high astigmatism and hyperopia become available in the near future.

POTENTIAL BARRIERS

What holds patients back from having refractive surgery? Financial considerations play a role. SMILE is considerably more expensive than LASIK, but it is not the primary obstacle in my view. It would be nice to be able to offer patients what is best for them, irrespective of the technique or the price, but that is not always possible. However, it is more transparent for patients, as they know that they are given advice purely on the medical merits of the case rather than any financial considerations.

There is also a psychological issue. Patients are aware that laser vision correction is surgery, and they can be afraid of complications. It is important that they have trust in their doctor, the technology, and the postoperative care team.

My feeling is that, in the future, we will see less demand for LASIK and surface ablation procedures as the demand for SMILE continues to grow. But LASIK, of course, will not disappear any time soon. I think there will be room for flap-based procedures for the foreseeable future, particularly for hyperopes who currently have less treatment options compared to myopes. The most important thing is to be able to offer our patients a range of safe, effective, and reliable procedures that deliver excellent quantity and quality of vision.

For the growing market of presbyopic patients, monovision can be a safe and effective option. If the patient is older than 50 years of age and has some issues with monovision, however, then an IOL procedure would be my first choice. The same applies to high myopes who tend to develop a cataract earlier. Once the retina is okay and there are no other contraindications, I would usually opt for an intraocular procedure for them as well.

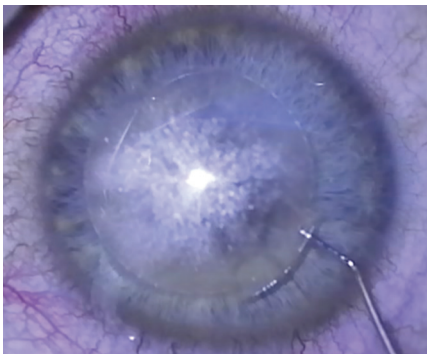

Figure 2. During SMILE, the lenticule will be removed through a small incision.

LEGACY OF LASER VISION CORRECTION

A very important point to bear in mind is that around 2% of patients currently presenting for intraocular surgery have undergone laser vision correction in the past—and the number is growing. Some patients, particularly hyperopes, have had high ametropic corrections years ago, and some of them had subsequent enhancements. The result is that we are often faced with a multifocal cornea, so implanting a multifocal IOL in these patients is not a viable treatment strategy because it generates optical phenomena and compromises quality of vision.

For those who have undergone surface ablation, it depends on the cornea: Is there presence of asphericity, higher-order aberrations, or irregular astigmatism, for instance? A multifocal IOL may still be an option if all is normal with the eye, but the calculation of IOL power is also less predictable for these complex eyes.

We need to engage with patients when they first come to our clinics requesting a refractive procedure, and we must explain that performing a hyperopic ablation might have implications if they opt for a multifocal lens in 10 or 15 years' time. We see a lot of patients after hyperopic treatment who can no longer have a multifocal lens and who might have made a different choice had they known about this possibility 5 or 10 years earlier. The long-term picture of ocular health should be in the forefront of the surgeon's mind when discussing treatment options with patients.

CONCLUSION

The laser vision correction market in Germany is changing due to demographic factors and the advent of new treatment options for patients. SMILE has transformed our refractive surgery practice because it delivers excellent visual outcomes, and it is well placed to capitalize on the growing demand for minimally invasive surgery. ■

1. Denoyer A, Landman E, Trinh L, Faure JF, Auclin F, Baudouin C. Dry eye disease after refractive surgery: Comparative outcomes of small incision lenticule extraction versus LASIK. *Ophthalmology*. 2015;122:669-676.
2. Bingjie W, Naidu RK, Chu R, Dai J, Qu X, Zhou H. Dry eye disease following refractive surgery: A 12-month follow-up of SMILE versus FS-LASIK in high myopia. *J Ophthalmol*. 2015. https://doi.org/10.1155/2015/132417.
3. Internal data on file, Carl Zeiss Meditec AG.

DANIEL KOOK, MD
- Private practice, Munich, Germany
- daniel.kook@med.uni-muenchen.de
- Financial disclosure: Consultant (Alcon, Carl Zeiss Meditec)

Getting the Most From SMILE Laser Vision Correction

Optimize the laser's energy settings to help patients achieve faster visual recovery.

BY DETLEV R.H. BREYER, MD

With growing popularity worldwide and a robust body of evidence in the scientific literature,[1-4] Small Incision Lenticule Extraction has firmly established its credentials as a safe, accurate, and efficacious refractive surgery procedure (Figure 1). I was fortunate to be one of the early adopters of the technology, and I performed my first procedure with SMILE using the VisuMax femtosecond laser (Carl Zeiss Meditec) in 2013.

My enthusiasm to move to this new approach to refractive surgery seemed like a natural evolution. I was convinced by the early results of and from conversations with Walter Sekundo, MD, PhD; Rupal Shah, MD; and other SMILE pioneers that this approach represented the future of minimally invasive refractive surgery. I have no cause to regret my decision: My practice volume multiplied by a factor of 4, and SMILE has completely replaced femtosecond LASIK with the exception of the procedures I perform in hyperopes and presbyopes.

At the beginning of our clinical experience with SMILE, we quickly realized that postoperative visual recovery took slightly longer than with LASIK in order for patients to attain 20/10 vision. It was also clear that this experience was not confined to our practice alone.[5,6] At that time in 2013, my approach to dealing with the delay in visual recovery was to tell patients about it upfront. I perform refractive surgery on Fridays. On the day of surgery, I would tell patients that when I would see them on their postoperative day 1 follow-up visit that their vision would not be perfect, but close to it. After relaxing on Sunday, they could then anticipate returning to their normal activities on Monday with full visual recovery.

FOCUS ON ENERGY SETTINGS

Although delayed visual recovery was a relatively minor drawback when weighed alongside the benefits of the procedure, including that it is a minimally invasive surgery and that there is no flap or flap-related complications, less dry eye than with other laser vision correction procedures, and excellent outcomes, it still merited further investigation in an effort to establish the root cause.

Given the known importance of laser energy settings for the surface regularity of the human corneal lenticule and posterior stroma, it was surmised that reducing the levels of femtosecond laser energy into the eye might have a positive impact on visual recovery in the immediate postoperative period.[7]

The concept of energy optimization is principally to balance the effects of femtosecond pulse energy (measured in nJ), tracking distance and spot separation to make sure the energy delivered into the eye is not too high or too concentrated in one area. If the energy is too high, an opaque bubble layer (OBL) will be created. Although OBL is not thought to affect clinical

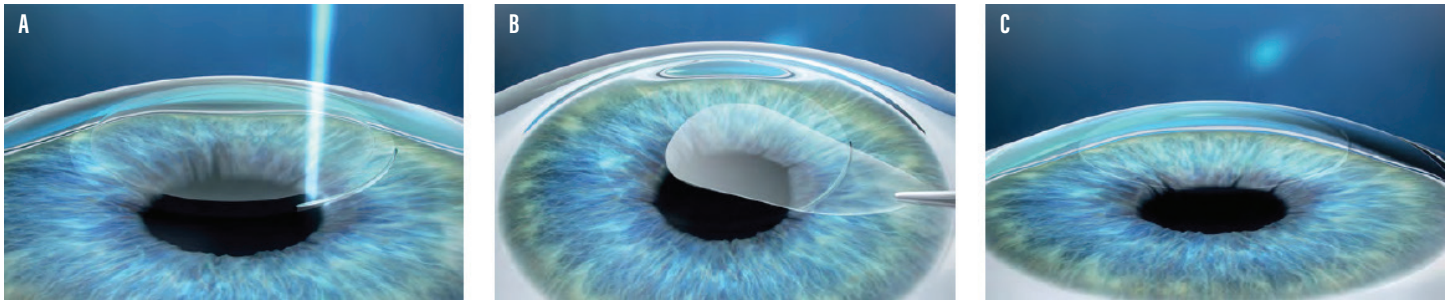

Figure 1. The three steps of Small Incision Lenticule Extraction: The creation of a refractive lenticule and a small incision in the intact cornea (A). The lenticule is removed through the small incision (B). Once the lenticule is removed, the corneal shape is altered, thereby achieving the desired refractive correction (C).

outcomes in the longer term, it can lead to delayed visual recovery or interfere with the penetration of femtosecond laser pulses. This can result in difficult tissue dissection and residual marginal lenticule.[8] It can also make it difficult to visualize and perform lenticule dissection. By contrast, if the energy levels are too low during SMILE, it can result in increased adhesions and become extremely difficult to separate the tissue in order to remove the lenticule. When this happens, the only option for the surgeon may be to abort SMILE entirely.

TWEAKING THE SETTINGS

SMILE performed on the VisuMax laser platform has three preset modes of treatment: (1) standard, (2) fast, and (3) expert. The standard mode is the default laser parameters set by the manufacturers, and the expert mode has modifiable laser settings that can be optimized by the surgeon according to his or her preferences and clinical experience. The fast mode, which consists of preset laser parameters customized according to region, may be altered only by ZEISS specialists.

In our experience with SMILE over many years, anything above an average energy offset of 35 and a pulse energy of 175 nJ is considered too high. A suboptimal energy setting is anything less than 20 offset and a pulse energy of 100 nJ, which is the plasma threshold level. The ideal energy level is located somewhere between 20 and 30 offset and 100 to 150 nJ and will vary slightly from laser to laser.

My advice for a surgeon just starting with SMILE is to follow the ZEISS SMILE onboarding process. A regional clinical application specialist will help to find the optimal settings for the laser. In general, it is preferable to use the lowest possible energy levels; however, if the surgeon notices black spots appearing on the cornea, he or she should not lower the energy settings any further. These spots are thought to form through the adherence of water droplets or meibomian secretions to the interface between the suction cone and cornea. They may locally block photodisruption and must be manually separated during lenticule dissection, so it is best to keep the energy setting sufficiently high to preclude their appearance.

In summary, the key to successful outcomes is to modulate the energy settings until a "sweet spot" of energy levels is obtained. This energy level is sufficiently high to ensure safe and easy tissue dissection yet low enough to avoid impacting the postoperative visual recovery.

BALANCING ACT

Finding the right energy level is a delicate balancing act, but with enough practice and by drawing on the experience of ZEISS representatives and other surgeons as required, it should be perfectly attainable for all refractive surgeons who opt to convert to SMILE. One particular sign to watch for when experimenting with settings is gas bubbles escaping from the incision site as it is opened. This is usually a positive sign that the sweet spot for energy optimization has been reached and smooth lenticule extraction can be assured without any negative impact on immediate postoperative visual recovery.

Since we optimized our energy settings, about 99% of our patients now attain binocular UCVA of 20/20 on postoperative day 1. It is no longer necessary to warn patients in advance of potential issues with their visual recovery, and most can drive and perform their usual activities within 24 hours of surgery.

Our own experience with lower energy settings has also been validated in some recent clinical studies. Donate and Thaëron, for instance, conducted a study assessing early visual and optical quality recovery after SMILE using laser energy level settings close to the plasma threshold. They found that this approach had minimal effect on ocular scatter, and it achieved better and faster visual recovery in patients with moderate myopia.[9] In another study by Ji et al, different energy levels in lenticule extraction were compared. The authors concluded that it may be advisable to reduce femtosecond laser energy to less than 115 nJ at a spot separation of 4.5 µm in order to achieve better visual outcomes with faster recovery after SMILE.[10]

SPOT SETTINGS AND OTHER PEARLS

One other important strategy to improve laser settings and enhance outcomes is to use differential spot spacing. Since collagen fibers are thinner and more compact in the upper corneal stroma and thicker and more dispersed in the lower stroma, it is advisable to set the spot distance slightly wider (4.5 µm) for the cap cut and slightly narrower (4.2 µm) for the lenticule cut. This makes a total energy output of 6.9 µm for the cap cut and 7.9 µm for the lenticule cut.

MAXIMIZE YOUR SETTINGS

ENERGY LEVEL

- The key to successful outcomes is to modulate the energy settings until a "sweet spot" of energy levels is obtained.
- An energy level that is too high is anything above an average energy offset of 35 and a pulse energy of 175 nJ.
- A suboptimal energy setting is anything less than 20 offset and a pulse energy of 100 nJ, which is the plasma threshold level.
- The ideal energy level is located somewhere between 20 and 30 offset and 100 to 150 nJ and will vary slightly from laser to laser.

SPOT SPACING

- It is advisable to set the spot distance slightly wider (4.5 µm) for the cap cut and slightly narrower (4.2 µm) for the lenticule cut.
- This makes a total energy output of 6.9 µm for the cap cut and 7.9 µm for the lenticule cut.

Surgeons who are already comfortable performing SMILE might gain additional benefit by using the "no dissection" technique for lenticule removal.[11] This technique was first described by Sri Ganesh, MD. After docking and laser delivery, a microforceps is used to grasp the lenticule and gently peel it from the underlying stromal bed, without performing any dissection of the upper and lower planes of the lenticule. For this technique, which Dr. Ganesh calls "lenticuloschisis," a minimum lenticule thickness of 25 to 30 µm is required. Initial results suggest lenticuloschisis produces a clearer and smoother interface postoperatively, which, apart from the new surgical technique, is also caused by optimizing energy levels below 115 nJ.

Another simple trick I like to teach beginners is not to hold their instruments too tightly in order to ensure a smoother dissection. The use of the Breyer-Pfäffl SMILE dissector that I developed in association with Geuder further improves the lenticule dissection, especially in more complex cases.

CONCLUSION

Optimizing energy settings with the VisuMax femtosecond laser helps to achieve a uniform smooth bubble layer with minimal adhesions and smoother lenticule removal. For the patient, optimal energy into the eye equates to faster visual recovery in the immediate postoperative period.

Based on the experience of hundreds of happy patients at our clinic, I believe SMILE currently offers the best and safest method to correct myopia and myopic astigmatism in suitable candidates. Its safety, effectiveness, predictability, and long-term results are scientifically well proven. ■

1. Hansen RS, Lyhne N, Grauslund J, Vestergaard AH. Small-incision lenticule extraction (SMILE): outcomes of 722 eyes treated for myopia and myopic astigmatism. *Graefes Arch Clin Exp Ophthalmol.* 2016;254: 399-405.
2. Pedersen IB, Ivarsen A, Hjortdal J. Three-year results of small incision lenticule extraction for high myopia: refractive outcomes and aberrations. *J Refract Surg.* 2015;31:719-724.
3. Blum M, Taubig K, Gruhn C, Sekundo W, Kunert KS. Five-year results of small incision lenticule extraction (ReLEx SMILE). *Br J Ophthalmol.* 2016;100:1192–1195.
4. Han T, Zheng K, Chen Y, Gao Y, He L, Zhou X. Four-year observation of predictability and stability of small incision lenticule extraction. *BMC Ophthalmol.* 2016;16:149.
5. Kamiya K, Igarashi A, Ishii R, Sato N, Nishimoto H, Shimizu K. Early clinical outcomes, including efficacy and endothelial cell loss, of refractive lenticule extraction using a 500 kHz femtosecond laser to correct myopia. *J Cataract Refract Surg.* 2012;38:1996–2002.
6. Shah R, Shah S. Effect of scanning patterns on the results of femtosecond laser lenticule extraction refractive surgery. *J Cataract Refract Surg.* 2011;37:1636-1647.
7. Kunert KS, Blum M, Duncker GI, Sietmann R, Heichel J. Surface quality of human corneal lenticules after femtosecond laser surgery for myopia comparing different laser parameters. *Graefes Arch Clin Exp Ophthalmol.* 2011;249:1417-1424.
8. Wang Y, Zhao K. Refractive Surgery with Femtosecond Laser. Beijing: People's Medical Publishing House. 2014:116–118.
9. Donate D, Thaëron R. Lower energy levels improve visual recovery in small incision lenticule extraction (SMILE). *J Refract Surg.* 2016;32:636-642.
10. Ji Y W. et al. Effect of lowering laser energy on the surface roughness of human corneal lenticules in SMILE. *J Refract Surgery.* 2017;33(9):617-624 .
11. Ganesh S, Brar S. Lenticuloschisis: A "no dissection" technique for lenticule extraction in small incision lenticule extraction. *J Refract Surgery.* 2017;33:563-566.

DETLEV R.H. BREYER, MD
- Owner, PremiumEyes and Breyer-Kaymak-Klabe Eye Surgery, Düsseldorf, Germany
- dr.detlev.breyer@gmail.com
- Financial disclosure: Medical advisory board (Carl Zeiss Meditec)

Hyperopic SMILE on the Horizon

A better option for hyperopia correction is coming.

BY PAVEL STODULKA, MD, PHD

Refractive surgery options for hyperopia have tended to lag behind advances in the treatment of myopia. LASIK, PRK, refractive lens exchange (RLE), and phakic IOLs have all been proposed treatments to correct low, moderate, or high hyperopia. Phakic IOLs have also been used to correct moderate or high hyperopia. Among these surgical techniques, LASIK is the most popular with younger patients (under age 40). RLE, a procedure I typically perform with trifocal IOL implantation, is the most popular choice for patients over 40 and for younger patients with high hyperopia, as quality of vision and stability of LASIK is questionable and refractive regression and unpredictable outcomes have been widely reported.

Hyperopes present a unique set of challenges for refractive surgeons. Compared to a normal emmetropic eye, a hyperopic eye typically has a short axial length; increased lens thickness; and, often, a small anterior segment and shallow anterior chamber depth, which is a contraindication for phakic lens implantation. Eyes with relatively flat corneal curvature and a thicker cornea are suited for a corneal laser refractive surgery procedure like hyperopic SMILE, as it is possible to significantly increase corneal curvature to correct hyperopia and continue to maintain postoperative visual quality.

Laser vision correction for hyperopic patients requires accurate preoperative assessment that must include cycloplegic refraction; this is a benchmark for setting surgical parameters. Precise centration during the surgery is also important for postoperative quality of vision. A larger treatment optical zone is required to minimize the potential induction of higher-order aberrations. Furthermore, a higher amount of tissue is removed during hyperopic compared to myopic ablations. Treating concomitant astigmatism, which is common in hyperopes, makes the surgery even more challenging. In most cases, surgical correction of refractive error also corrects accommodating esotropia, but sometimes a separate squint surgery is required.

An alternative approach to treating hyperopia using the lenticule extraction technique was first investigated in 2010. Although technically more difficult than myopic lenticule extraction, the investigators concluded that hyperopic lenticule extraction was feasible and merited further research. The results of the initial study, published 2 years later, were promising, but some eyes experienced similar problems to hyperopic LASIK, with a loss of corrected distance visual acuity and a significant degree of regression. It was surmised that the regression was most probably due to the treatment's small transition zone size (<2.0 mm).

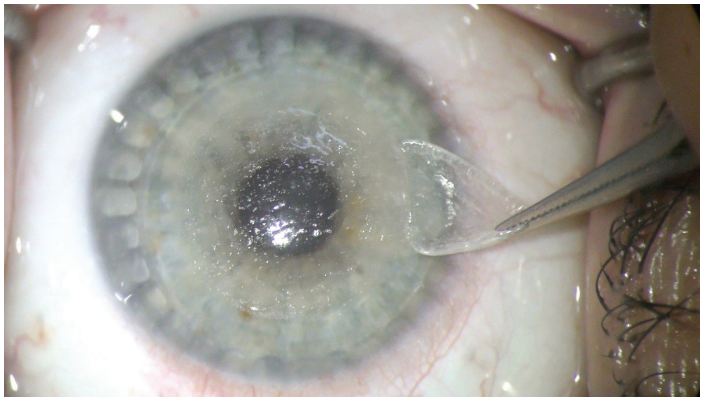

Figure 1. Lenticule removal during hyperopic SMILE.

SOFTWARE IMPROVEMENTS

Since then, refinements have been made to hyperopic lenticule removal using the SMILE technique (Figure 1). An improved nomogram, alterations to the lenticule geometry, a larger transition zone of 2.0 mm, and optimized energy settings on the VisuMax femtosecond laser (Carl Zeiss Meditec), the proprietary laser used to perform SMILE, have successfully resolved many of the problems encountered in the first series of cases.

To validate the safety and efficacy of these modifications, our clinic was selected to participate in a multicenter SMILE for hyperopia study, which involves six centers in Europe and three in Asia (two in China and one in India). The study will include up to 374 eyes, with hyperopia of 6.00 D or less and cylinder of 5.00 D or less. The highest intended correction is 7.00 D at the most hyperopic meridian, leading to a maximum postoperative keratometry (K) reading of 51.00 D. The primary endpoints of the study are safety and effectiveness as measured by corrected distance visual acuity (CDVA) and uncorrected distance visual acuity (UDVA). Secondary endpoints include contrast sensitivity, topography measurements, and subjective quality of vision questionnaires (see the sidebar *At a Glance: SMILE for Hyperopia Study*).

The study is ongoing. Initial results from our own cohort of patients (N=53) have been promising and augur well for the overall trial results, which will hopefully be announced in the near future. In

our clinic, 102 eyes have already been successfully treated, including those with high astigmatism.[1]

The objective visual outcomes compare favorably with those obtained with hyperopic LASIK in the published literature. There was also a very high level of patient satisfaction, which indicates very good predictability. We believe that the wide optical zone after hyperopic SMILE provides a very good quality of vision, which is often difficult to achieve with LASIK. Regression and long-term stability must be confirmed with longer follow-up. We have also had very good results in eyes with high cylinders, leading us to believe that high astigmatism correction can be effectively combined with hyperopia correction. Interestingly, patients with higher corrections tended to be the happiest postoperatively because they derived the maximum benefit from the procedure.

The principle of hyperopic SMILE is not radically different from the principle used in myopic treatments, but it differs in terms of the geometry of the extracted lenticule. For hyperopic eyes, a negative doughnut-shaped lenticule with a diameter of 7.5 mm or more is created, which is thinner in the center and thicker in the periphery. After removal, the overlying anterior stroma remodels to create a steeper corneal profile and to correct the ametropia.

AT A GLANCE: SMILE FOR HYPEROPIA STUDY

PARTICIPATING CENTERS

- Six centers in Europe
- Two centers in China
- One center in India

PATIENT POPULATION

- Up to 374 eyes with hyperopia of 6.00 D or less and cylinder of 5.00 D or less
- The highest intended correction is 7.00 D at the most hyperopic meridian, leading to a maximum postoperative keratometry reading of 51.00 D
- Primary endpoints: safety and effectiveness as measured by CDVA and UDVA
- Secondary endpoints: contrast sensitivity, topography measurements, and subjective quality of vision questionnaires

FIRST STEPS

We performed our first hyperopic SMILE procedure in October 2017 and were pleased that the surgery was relatively straightforward and the patient obtained a very good visual outcome. As we enrolled more patients and became more familiar with the procedure, the results continued to be impressive. We also became more accomplished at lenticule manipulation and extraction, and the procedure became routine.

From a surgical perspective, hyperopic SMILE is more challenging than its myopic counterpart. The reason is that the lenticule is about 8 mm, which is wider than the lenticule in myopic SMILE. It takes a bit longer to create the lenticule with the laser and to manually detach and remove it. With the longer laser surgery time, there is an increased risk that the patient will not fixate properly during the creation of the lenticule. However, this risk is largely theoretical, as it has not happened during surgery in our first 100 eyes.

Figure 2. Docking the interface on the patient's eye.

The other challenge with the wider lenticule is that the incision is positioned closer to the limbus, where the blood vessels are located, which can increase the risk of bleeding and can interfere with the creation of the femtosecond laser cuts, including the entry to the incision for lenticule extraction, and, therefore, the smooth completion of surgery. Again, however, the risk is rather low, as we have not encountered this issue with our patients and have always managed to successfully conclude the surgery.

I also know that some other surgeons performing hyperopic SMILE avoid this problem either by performing a temporal incision, which is further away from the limbus, or by creating a second incision as a backup to enable them to proceed with the surgery in the event of difficulties in opening the first incision. I have never had to use this approach with a second incision, but it is good to know that this option is available if required.

In terms of complications, we did experience some mild haze in a few early patients, but we resolved this by reducing the energy settings slightly. We also had some transitory dry eye and some incidence of halos and glare at night, but these resolved spontaneously and were less significant compared to what we have experienced with hyperopic LASIK patients over the years. There were no issues with suction loss or torn or incomplete lenticule extraction.

SURGICAL PEARLS

For surgeons interested in adopting hyperopic SMILE when it becomes available, I would advise not to operate on low hyperopia early in the learning curve. The thinner lenticule in these patients is more difficult to manipulate.

EARLY STUDY RESULTS FROM ANOTHER HYPEROPIC SMILE STUDY SITE[1]

PURPOSE

- Evaluating the visual and refraction outcomes of SMILE for hyperopia

STUDY DESIGN

- Prospective study of vertex-centered hyperopic SMILE treatments in 93 eyes
- Inclusion criteria: maximum attempted hyperopic meridian between 1.00 and 7.00 D, CDVA of 20/40 or better
- Lenticule parameters: 6.3 to 6.7 mm diameter, 2-mm transition zone, 30 µm thickness, 120 µm cap thickness
- 3-month follow-up data included contrast sensitivity with the Functional Vision Analyzer

RESULTS

- 82 eyes were available for follow-up
- Attempted spherical equivalent refraction: 5.62 ±1.20 D (range, 1.00–6.90 D)
- Attempted cylinder: -0.91 ±0.68 D (range, 0.00 to -3.50 D)
- Emmetropia target (n = 36): UDVA of 20/40 or better in 89%
- Spherical equivalent refraction relative to target: -0.17 ±0.85 D (range, -2.20 to 3.00 D)
- 59% and 76% of eyes were within ±0.50 and ±1.00 D of target refraction, respectively
- No clinically significant change in contrast sensitivity

CONCLUSION

- At 3 months postoperative, results with hyperopic SMILE in this population were promising

1. Reinstein DZ, Pradhan KR, Carp GI, Archer TJ, Day AC, Sekundo W, Dhungana P. Small incision lenticule extraction for hyperopia: 3-month refractive and visual outcomes. *J Refract Surg.* 2019;1;35:24-30.

For preoperative assessment, the maximum K reading after the surgery should be lower than 51.00 D, so it should be calculated preoperatively. Patients with steeper corneas or high hyperopia or a combination of these factors must be screened carefully and might not be eligible for hyperopic SMILE surgery. Dry eye can also be a contraindication, although this is not as critical as with hyperopic LASIK, in my opinion. Hyperopic SMILE should not be performed in unstable or irregular corneas because it would require a significant amount of corneal stroma, which can potentially induce ectasia. Finally, based on common surgical sense, patients with serious pathologies, recurrent or acute infections, ocular inflammation, or cataract or retinal disease will also not be good candidates for this treatment. Many of these exclusion criteria are not specific to SMILE but apply to all laser vision correction procedures.

Before the start of surgery, it is important to clean the cornea thoroughly and rinse out all debris. In terms of anesthesia, we instill a few oxybuprocaine drops into the eye a few seconds before inserting the speculum and commencing the docking procedure (Figure 2). Be careful not to instil too many drops over a long period of time before surgery, as the cornea might become slightly less transparent and interfere with the laser action.

As with myopic SMILE procedures, it helps to talk to the patient during the treatment phase, reassuring him or her and asking that he or she maintains proper fixation. I find this helps to keep the patient calm and concentrated and leads to safer surgery and better outcomes. If the patient is nervous and the eye is moving around a lot, it increases the risk of failure considerably. Our feedback from the patients has been positive, and they often remark how pain-free and comfortable they found the treatment. Sometimes they don't even realize that we have completed the procedure—it really is that smooth and efficient.

We target plano refraction in our hyperopic procedures and have found that the results have been excellent with this approach, although this must be verified with longer follow-up. With any hyperopic corneal procedure, there is marginally slower visual rehabilitation after the surgery, but I think this is probably something that is noticed more by the surgeon than by the patient.

Patients notice the "wow" factor at the first follow-up visit, especially higher hyperopes. We have found that patients are better informed and will often come to the clinic specifically asking for SMILE. This is usually because they have a friend or family member who had the treatment and were happy with the outcome. Word-of-mouth is a big factor in the growth of SMILE.

CONCLUSION

The road to developing hyperopic SMILE has been long and occasionally difficult, but we have learned a lot along the way and have emerged with a treatment that I believe delivers high-quality visual outcomes with minimal complications.

Regulatory approval in the near future should give us a much-needed option for hyperopic patients who want to take advantage of the growing trend toward minimally invasive surgery. I think we will see a big demand for SMILE for hyperopia from our young hyperopic patients and a subsequent reduction in RLE rates. Based on my own results in more than 100 cases, I no longer perform hyperopic LASIK—the corneas are better postoperatively and the visual results superior, in my hands, with hyperopic SMILE. ■

1. Stodulka P. Correction of hyperopia with hyperopic astigmatism by ReLEx SMILE: a case report. Paper presented at: the ESCRS Winter Meeting; February 15-17, 2019; Athens, Greece.

PAVEL STODULKA, MD, PHD
- Chief Eye Surgeon, CEO, Gemini Eye Clinics, Czech Republic
- stodulka@lasik.cz
- Financial disclosure: None acknowledged

The Rich Promise of Lenticule Transplantation in Keratoconus

The procedure and the use of the VisuMax femtosecond laser (Carl Zeiss Meditec) as described in this article is off-label and not covered by the CE-Certificate of the device.

A brief history of stromal lenticule addition keratoplasty.

BY LEONARDO MASTROPASQUA, MD; AND MARIO NUBILE, MD


Small Incision Lenticule Extraction has become increasingly popular for the treatment of refractive errors. Today, more than 2 million SMILE surgeries for myopia and myopic astigmatism have been performed worldwide. In myopic SMILE, an intrastromal lenticule is created by the VisuMax femtosecond laser (Carl Zeiss Meditec), dissected, and then subsequently removed through a small incision. At this point, the lenticule is deemed to have served its useful purpose and is typically thrown away after surgery. That equates to 2 million discarded lenticules, which is a lot of wasted tissue.

In recent years, a number of researchers, including our own team in Italy, have been investigating whether it might be feasible to make better use of the discarded lenticules. In theory, the lenticules obtained from donor corneas could be used to insert tissue into a pathological cornea in order to potentially treat conditions such as hyperopia, presbyopia, keratoconus, ectasia, and certain corneal dystrophies.

FIRST STEPS

In 2012, the initial feasibility studies in animal models, conducted by Jodhbir S. Mehta, BSc(Hons), MBBS, FRCOphth, FRCS(Ed), FAMS, and colleagues at the Singapore National Eye Institute, demonstrated that lenticules could be successfully cryopreserved and re-implanted in animals with a high degree of safety.[1] The results led some to hypothesize that lenticules could be reused to correct refractive errors in other eyes, and preliminary reports were published on the implantation of myopic lenticules to treat hyperopia and presbyopia.[2-4]

The work at our research center in Italy has focused primarily on the possibility of using implanted lenticules to reshape and stabilize the corneas in eyes with progressive keratoconus. The basic idea is to implant the lenticules intrastromally in order to improve the geometrical quality of pathological corneas affected by keratoconus (Figure 1).

The procedure entails implanting a negative meniscus-shaped lenticule that is thinner in the center and thicker in the periphery—the geometric opposite of a myopic lenticule. Implanting a myopic lenticule will not work, as it increases the tissue volume in the center of the cornea where the apex of the cone is located and further steepens the corneal curvature. Implanting a negative meniscus-shaped lenticule theoretically leads to augmentation in thickness and central corneal flattening similar to the arc-shortening effect achieved with intrastromal corneal ring segments. This is achieved by placing the thickest part of the lenticule in the mid-periphery of the cornea.

Our first ex vivo study was published in 2016.[2] In that study, we used 12 stromal hyperopic lenticules created by the VisuMax femtosecond laser and evaluated them with OCT and topography after they were implanted into a pocket created by a femtosecond laser. The results were positive, showing that implantation of the lenticules was a feasible and reproducible technique to achieve central corneal flattening and increased thickness. We then repeated the same technique in a model of keratoconus-shaped corneas and successfully improved the curvature and corneal thickness in the pathologic models as well.

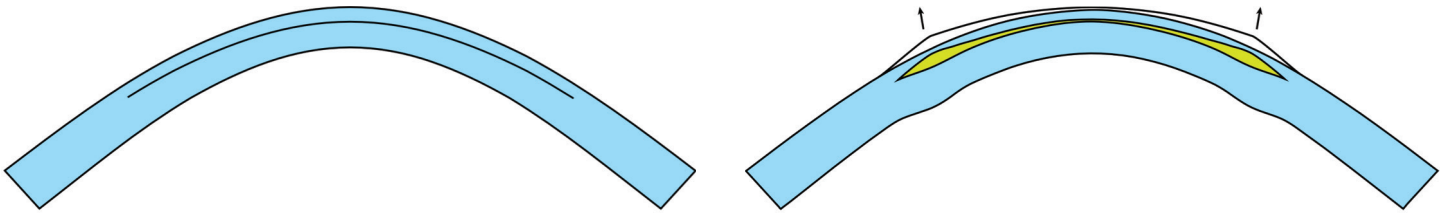

Figure 1. Drawing depicting the SLAK procedure: The negative meniscus-shaped lenticule is implanted intrastromally to improve the geometrical quality of keratoconic corneas.

HUMAN TRIALS

We then tested the procedure, called stromal lenticule addition keratoplasty (SLAK), in 10 patients with advanced keratoconus.[3] The 6-month results confirmed our earlier results in donor corneas and was shown to clinically efficiently improve the corneal shape and regularity in all patients with keratoconus. SLAK significantly improved the mean uncorrected and corrected distance visual acuity, and OCT scans confirmed a statistically significant increase in the thickness of the central and mid-peripheral cornea produced by the lenticule implantation.

The complication rate was extremely low with SLAK, and there was no incidence of graft rejection in any eyes. It is well known that lamellar keratoplasty has a very low risk of stromal rejection, so these patients do not need long-term steroid therapy after lenticule implantation.

We have used the SLAK technique to date in 32 patients, and we have up to 18 months of follow-up (Figure 2). Thus far, the results are very promising—even more so when one considers that the alternative for these advanced keratoconus patients was an invasive penetrating or deep lamellar keratoplasty. The concept of SLAK is to offer minimally invasive surgery that is efficient and reproducible. We believe that every technique that aims to compete with the gold standard should be not only efficient but also reproducible and within the scope of all surgeons' abilities.

SLAK surgery is not that technically difficult to perform. The stromal pocket in which the lenticule is implanted is easily created with a femtosecond laser, and it only takes a few seconds to create. The lenticule is then sculpted in the donor cornea with the exact shape, size, and geometry required using the VisuMax femtosecond laser, and it is extracted for implantation.

With the eye under topical anaesthesia, the lenticule is implanted through the stromal incision in the pocket. Once in place, the lenticule is distended and centered on the apex of the cornea according to the topography. The entire procedure takes about 3 to 4 minutes, and patients wear a contact lens for 1 day postoperatively. They are free to return to normal activities within 2 to 3 days of surgery—it truly merits the term minimally invasive surgery.

WHAT IS SLAK?

Stromal Lenticule Addition Keratoplasty entails implanting a negative meniscus-shaped lenticule that is thinner in the center and thicker in the periphery—the geometric opposite of a myopic lenticule—to reshape and stabilize the corneas in eyes with progressive keratoconus.

The basic idea of SLAK surgery is to implant the lenticules intrastromally in order to improve the geometrical quality of pathological corneas affected by keratoconus.

LESSONS LEARNED

A few key points about SLAK are worth noting. First, the best visual acuity outcomes were obtained in the less-advanced keratoconus cases. This is logical if one considers that flattening a cone in the eyes of advanced keratoconus patients usually only brings them back to a moderate disease level, so their visual acuity is still severely compromised by corneal steepening. However, treating a patient with moderate keratoconus and obtaining 40% improvement in his or her curvature brings the patient closer to normal levels of curvature and, therefore, better visual acuity. The key lesson is that the earlier we can intervene in the disease process, the better the outcomes will be.

This is not to suggest, of course, that we should treat patients who can tolerate a contact lens at the very early stages of keratoconus. If a patient has 20/20 visual acuity with a contact lens and is happy with that solution, then we do not propose any kind of surgery. However, most patients do not see well with spectacles and cannot tolerate contact lenses, or they become intolerant at a later stage and will seek other solutions if their keratoconus is progressing.

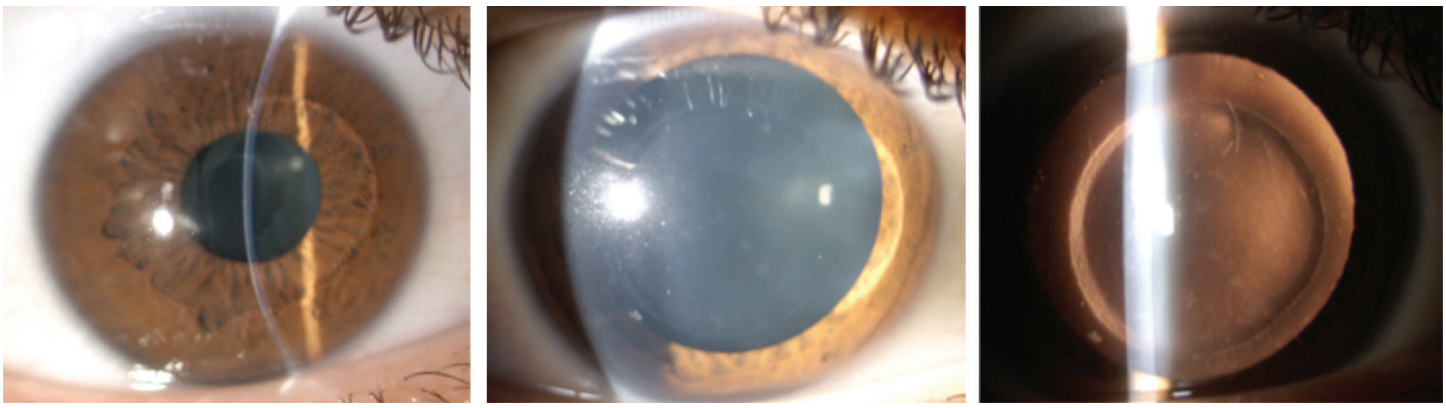

Figure 2. SLAK in advanced keratoconus: The stromal interface transparency was stable over 18 months of follow-up (left to right).

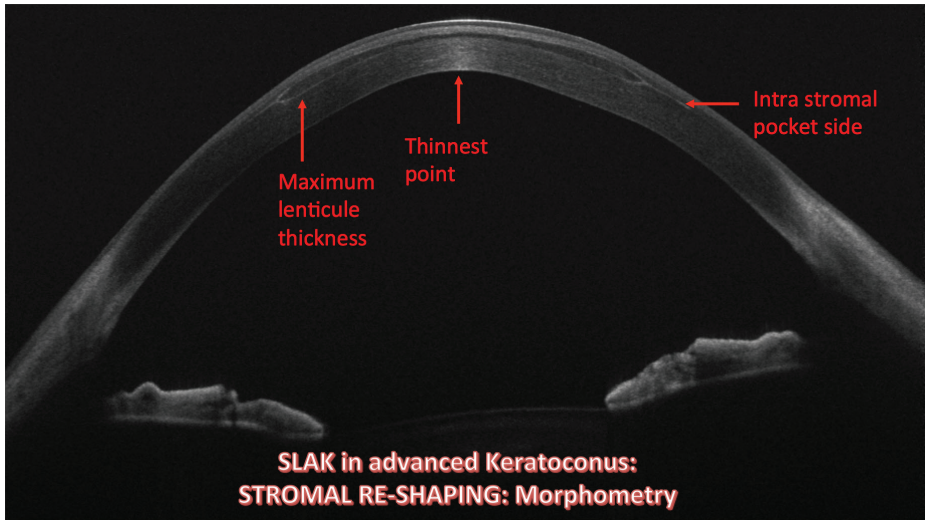

Figure 3. Widefield swept source OCT scan revealing that the lenticule was correctly placed inside the pocket with a peripheral bulging of the anterior and posterior surface.

COMBINED WITH CXL

Going forward, another potentially interesting application of SLAK will be in combination with CXL, a proven and widely used modality to improve the tensile strength of the cornea and halt the progression of keratoconus. The idea would be to use CXL to lock in the strong results of the reshaping that have already been achieved with the lenticule implantation.

Lenticule implantation could also be performed in patients with progressive keratoconus and very thin corneas that are below the safety margin for CXL. Performing SLAK in these patients would create sufficient thickening in the thinnest part of the cornea, enabling them to become eligible for CXL. It is these patients who are likely to derive the maximum benefit from SLAK since they cannot undergo CXL, their keratoconus is progressing, and they are facing penetrating or lamellar keratoplasty in the near future. By performing SLAK, we make the patient suitable for CXL, delay or halt their keratoconus progression, and improve their vision as well.

Likewise, SLAK may also benefit patients who are contact lens intolerant and who may require keratoplasty in the near future. Improving their corneal curvature by around 30% to 40% may enable them to wear a contact lens once again and avoid the need for invasive graft surgery. With this minimally invasive approach, we potentially have a wide range of positive effects for many different categories of patient.

The promise of lenticule implantation is exciting, but much remains to be done to bring this technique into mainstream practice. Therefore, we recently established an international research group, whose members include many renowned surgeons in the field of cornea, such as Harminder Singh Dua, CBE, FRCS (UK); Béatrice Cochener, MD, PhD (France), Jorge L. Alió, MD, PhD and Jorge L. Alió del Barrio (Spain), Josè L. Guell, MD, PhD (Spain), Jodhbir S. Mehta, BSc(Hons), MBBS, FRCOphth, FRCS(Ed), FAMS (Singapore), and our own team in Italy.

The goal is to pool research in this developing field, avoid single-center bias, perform multicenter trials, and set standards and protocols for the technique of lenticule implantation for the benefit of the wider ophthalmological community. Another broad aim of the group will be to promote the creation of a European eye bank to preserve tissues and lenticules donated by refractive surgery patients that could be processed and certified for eventual clinical use.

CONCLUSION

Although it is still early and more studies with longer follow-up are needed, the SLAK procedure has been shown to be safe and clinically efficient in improving the corneal shape (Figure 3) and vision in patients with keratoconus. ■

1. Angunawela RI, Riau AK, Chaurasia SS, Tan DT, Mehta JS. Refractive lenticule re-implantation after myopic ReLEx: a feasibility study of stromal restoration after refractive surgery in a rabbit model. *Invest Ophthalmol Vis Sci.* 2012;53:4975-4985.
2. Ganesh S, Brar S, Rao P, et al. Cryopreservation of extracted corneal lenticules after small incision lenticule extraction for potential use in human subjects. *Cornea.* 2014;33:1355-1362.
3. Sun L, Yao P, Li M, Shen Y, Zhao J, Zhou X. The safety and predictability of implanting autologous lenticule obtained by SMILE for hyperopia. *J Refract Surg.* 2015;31:374-379.
4. Lim CH, Riau AK, Lwin NC, Chaurasia SS, Tan DT, Mehta JS. LASIK following small incision lenticule extraction (SMILE) lenticule re-implantation: a feasibility study of a novel method for treatment of presbyopia. *PLoS One.* 2013;8:1-12.
5. Mastropasqua L, Nubile M. Corneal thickening and central flattening induced by femtosecond laser hyperopic-shaped intrastromal lenticule implantation. *Int Ophthalmol.* 2016;37:893-904.
6. Mastropasqua L, Nubile M, Salgari N, Mastropasqua R. Femtosecond laser-assisted stromal lenticule addition keratoplasty for the treatment of advanced keratoconus: a preliminary study. *J Refract Surg.* 2018;34(1):36-44.

LEONARDO MASTROPASQUA, MD
- Excellence Eye Research Center, University Gabriele d' Annunzio of Chieti, Pescara, Italy
- leonardo.mastropasqua@unich.it
- Financial disclosure: None acknowledged

MARIO NUBILE, MD
- Excellence Eye Research Center, University Gabriele d' Annunzio of Chieti, Pescara, Italy
- nubilemario@gmail.com
- Financial disclosure: None acknowledged

CRST EUROPE
Cataract & Refractive Surgery Today

EN_34_021_0057II
Printed inVIII/2019