MHz Swept Source Optical Coherence Tomography of the Choriocapillaris

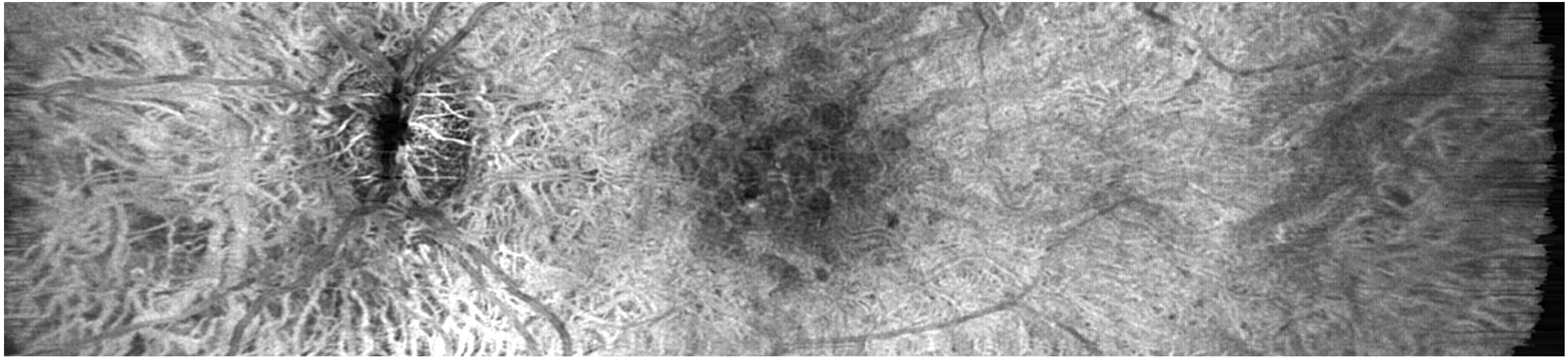

Tilman Schmoll, Michael Niederleithner, Anja Britten, Philipp Matten,
Luis de Sisternes, Simon Bello, Sophie Kubach, Wolfgang Drexler, Rainer A. Leitgeb

Disclosures

Carl Zeiss Meditec, Inc. (CZMI), Dublin, CA, USA

- Tilman Schmoll, PhD: CZMI (E)
- Luis de Sisternes, PhD: CZMI (E)
- Simon Bello, PhD: CZMI (E)
- Sophie Kubach, PhD: CZMI (E)

Medical University of Vienna, Austria

- Michael Niederleithner, MS: CZMI (C)
- Anja Britten, MS: CZMI (C)
- Philipp Matten, MS: CZMI (C)
- Wolfgang Drexler, PhD: CZMI (C)(F)
- Rainer Leitgeb, PhD: CZMI (C)(F)

The Choriocapillaris

- Thin layer of densely packed capillaries directly beneath Bruch's membrane

- Imaging and quantifying the choriocapillaris is believed to:
  - Improve the understanding of disease pathogenesis
  - Enable earlier diagnosis
  - Monitor disease progression

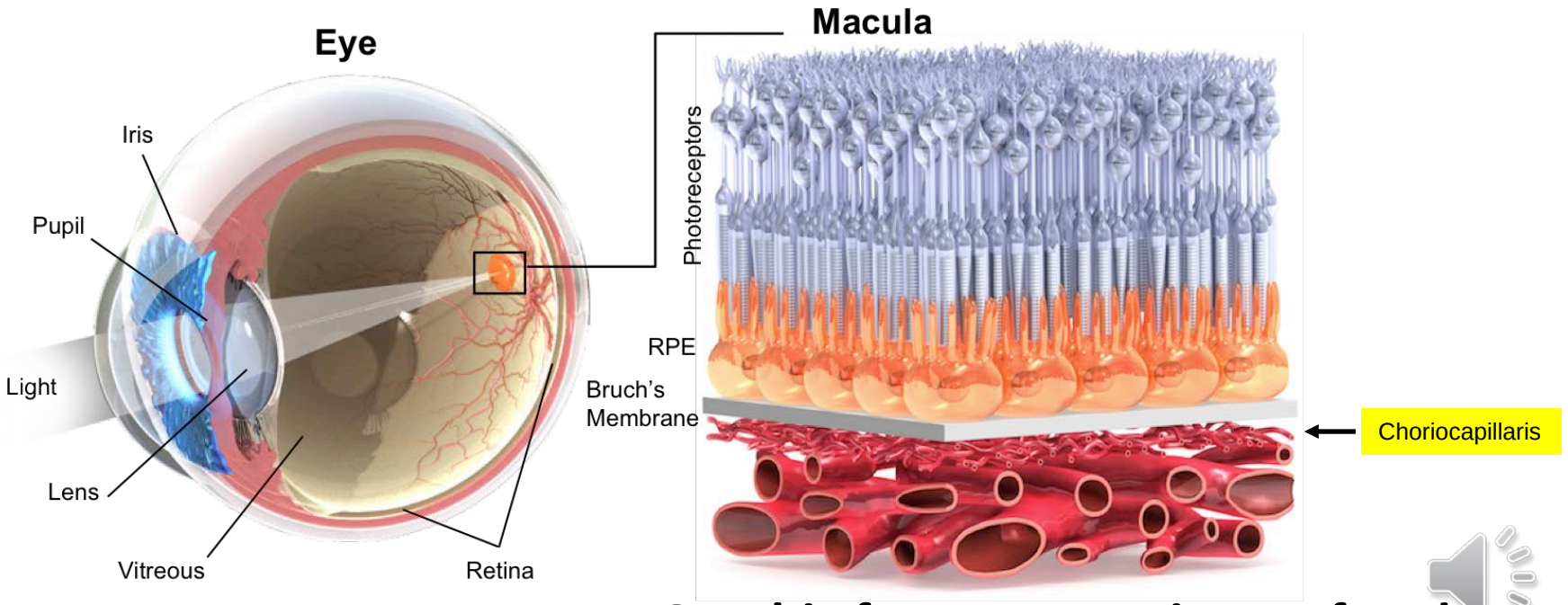

Graphic from www.scienceofamd.org

Why is it so difficult to image the Choriocapillaris?

- **Densely packed capillaries**
  - Vessel diameters close to the resolution limit of ophthalmic OCT systems, i.e. 10 µm to 20 µm

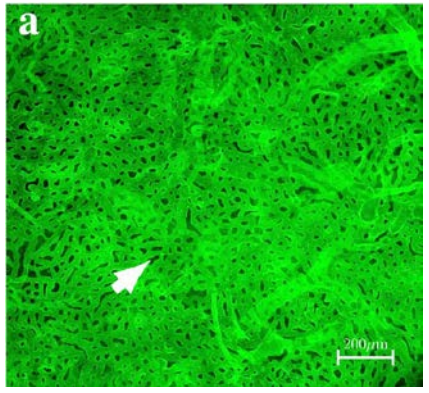

M.A. Zouache, et al., "Form, shape and function: segmented blood flow in the choriocapillaris, " Sci. Rep. 2016

- **Very thin layer**
  - ~20 µm thick
  - following the curvature of the eye
  - Prone to segmentation errors

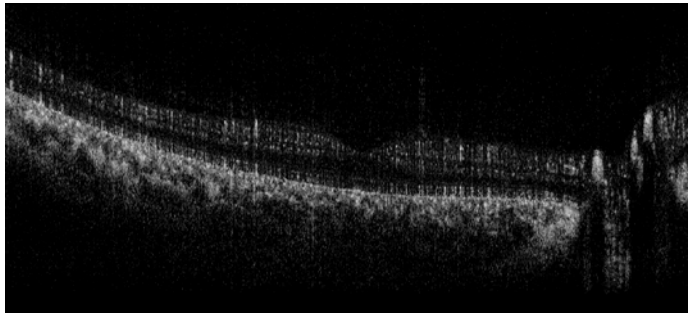

- **Projection artifacts**
  - Decorrelation tails of retinal vessels may look like choroidal vessels

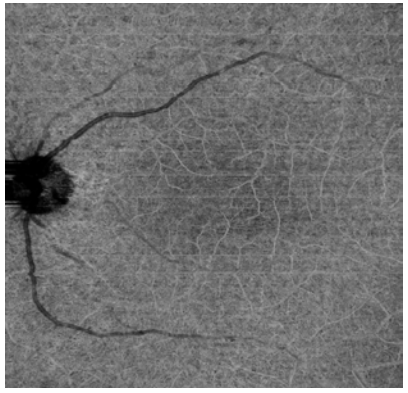

- **Below the retinal pigment epithelium**
  - Strongly scattering RPE is deteriorating spatial resolution and phase correlation

Are we really seeing capillaries?

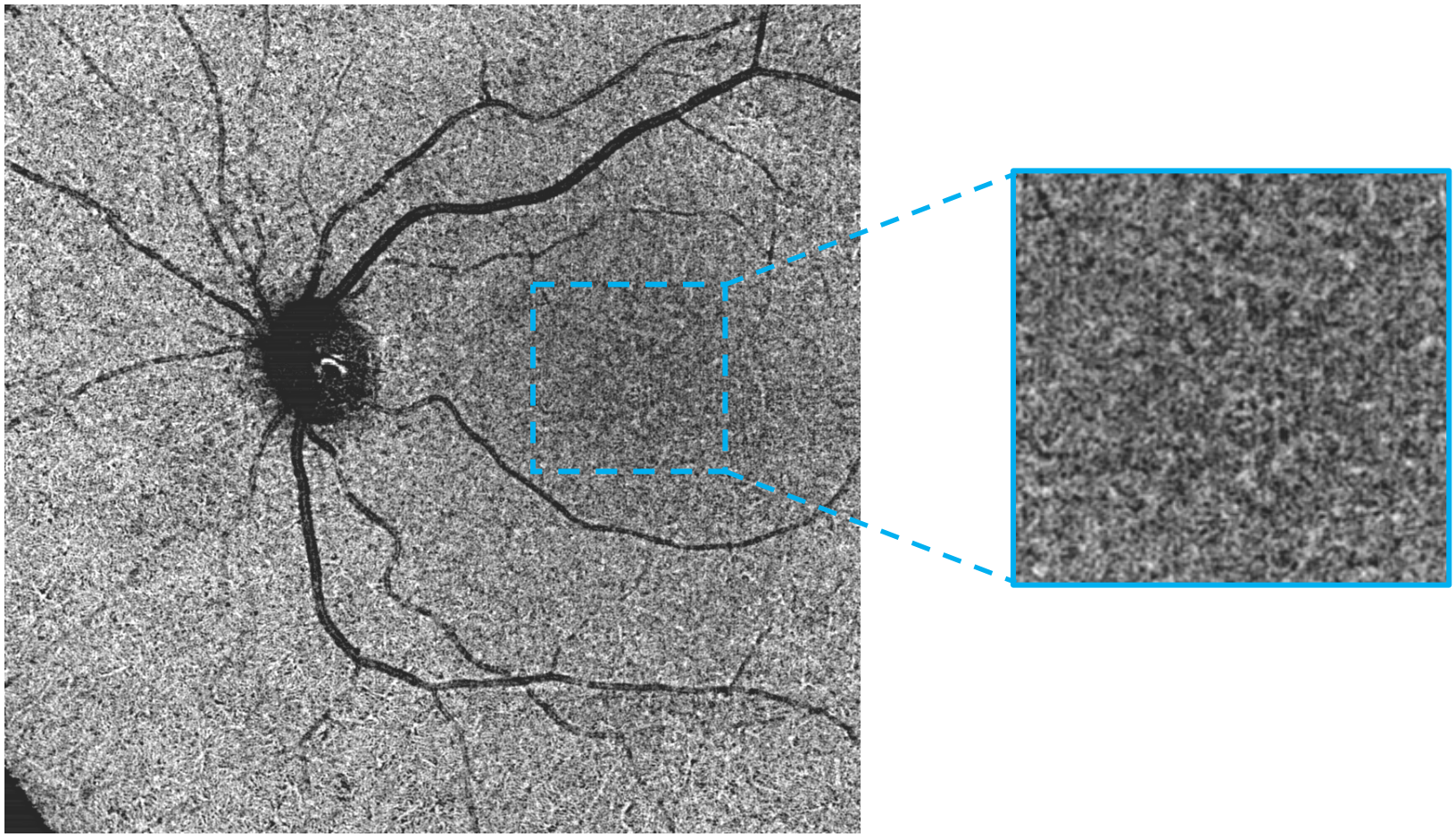

Can OCT produce features that look like capillaries?

- The convolution of sub-resolution features with an OCT system's Gaussian point spread function generates a structure which resembles a very dense capillary network
- Gaussian filters, commonly used to denoise OCTA images, enhance this effect further

input noise frame:





after convolution with Gaussian kernel:



increasing kernel size

OCTA images of the Choriocapillaris can be misleading

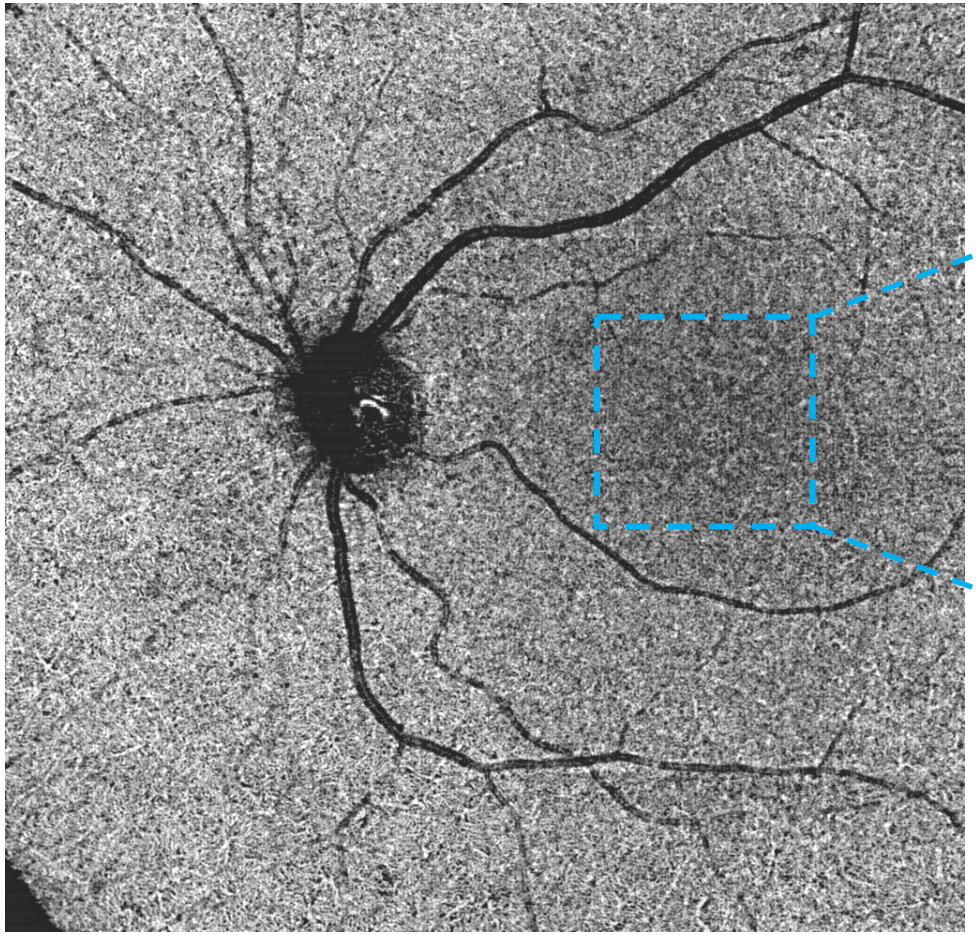

ZOOM IN



convolution of white noise with a Gaussian kernel



High lateral resolution OCT shows how actual capillaries look like…

2.4 µm lateral resolution:



K. Kurokawa, Z. Liu, D.T. Miller, "Adaptive optics optical coherence tomography angiography for morphometric analysis of choriocapillaris," Biomed. Opt. Express 2017

18.9 µm, 8.4 µm and 6 µm lateral resolution:

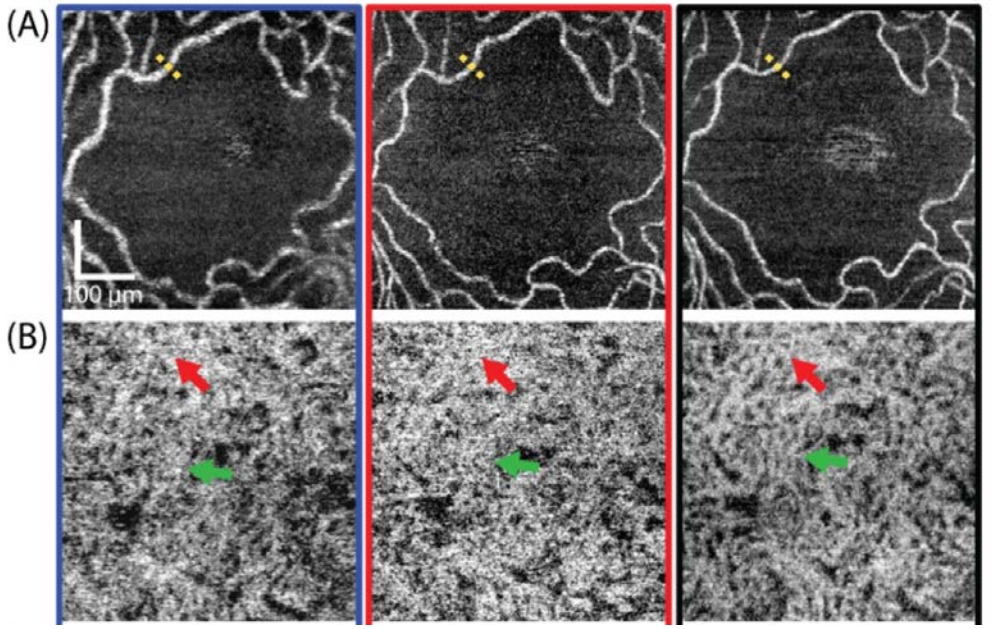

K. Zhou, S. Song, Q. Zhang, Z. Chu, Z. Huang, R.K. Wang, "Visualizing choriocapillaris using swept-source optical coherence tomography angiography with various probe beam sizes, " Biomed. Opt. Express 2019

Averaging helps a lot, too!

single scan



average of 7 scans



ZEISS PLEX® Elite 9000
3 mm x 3 mm, 300 a-scans x 300 b-scans x 4 b-scan repetitions
~14 µm lateral resolution

A. Uji et al., "Choriocapillaris Imaging Using Multiple En Face Optical Coherence Tomography Angiography Image Averaging," JAMA ophthalmology 2017

Comparison with Adaptive Optics OCT

single scan



average of 7 scans



ZEISS PLEX® Elite 9000
3 mm x 3 mm, 300 a-scans x 300 b-scans x 4 b-scan repetitions
~14 µm lateral resolution

***AO OCT image courtesy of Prof. Dr. Donald Miller, Indiana University**
K. Kurokawa, Z. Liu, D.T. Miller, "Adaptive optics optical coherence tomography angiography for morphometric analysis of choriocapillaris," Biomed. Opt. Express 201

Combining high lateral resolution and averaging

Modified ZEISS PLEX® Elite 9000

- 8 µm lateral resolution (FWHM)
- 2.25 mm x 2.25 mm
- 300 (a-scans) x 300 (b-scans)
  x 4 (b-scan repetitions)

Single Scans



Images provided by:
Dr Ramin Tadayoni and Dr Sophie Bonnin
Hôpital Lariboisière, Paris, France

Combining high lateral resolution and averaging

Modified ZEISS PLEX® Elite 9000

- 8 µm lateral resolution (FWHM)
- 2.25 mm x 2.25 mm
- 300 (a-scans) x 300 (b-scans)
  x 4 (b-scan repetitions)

Average of 7 scans

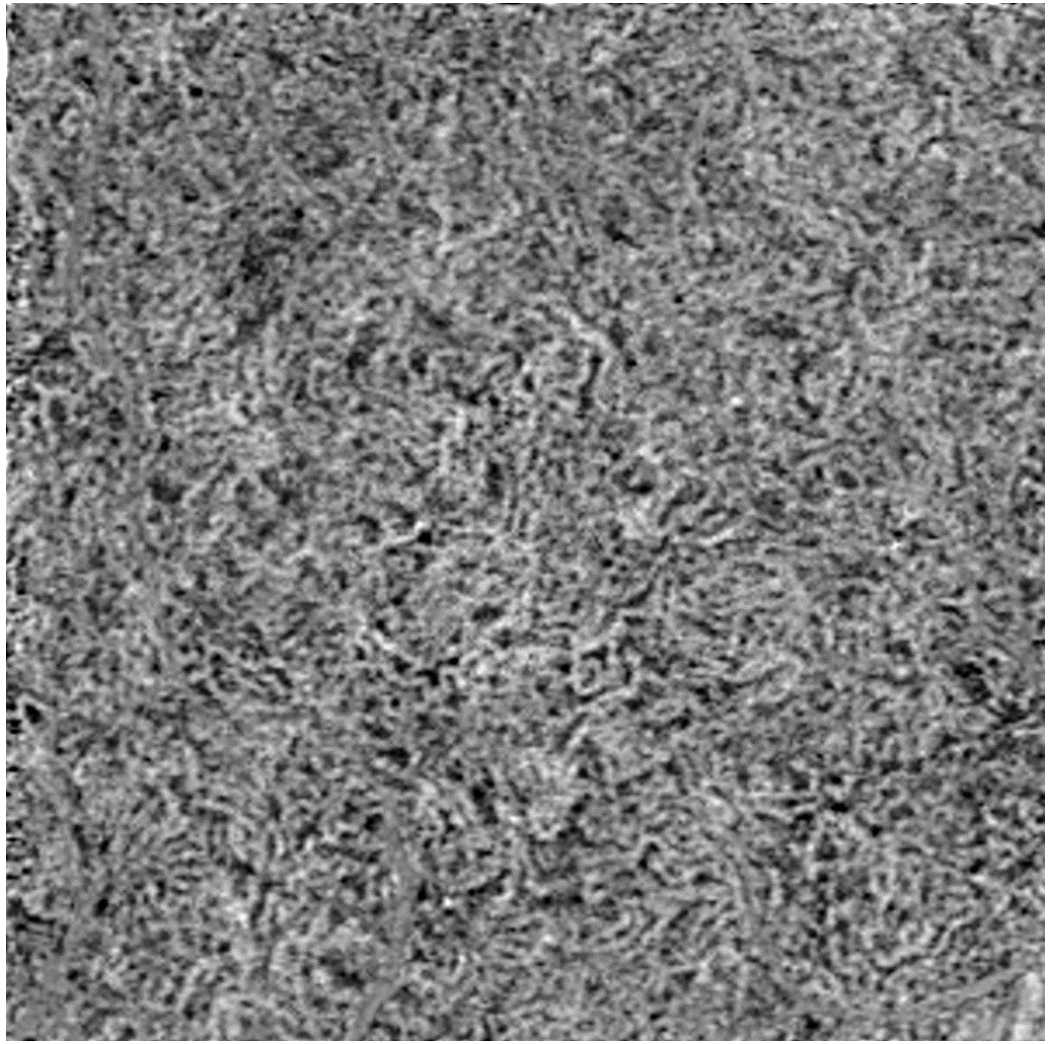

Images provided by:
Dr Ramin Tadayoni and Dr Sophie Bonnin
Hôpital Lariboisière, Paris, France

Combining high lateral resolution and averaging

Single Scans



Average of 7 scans

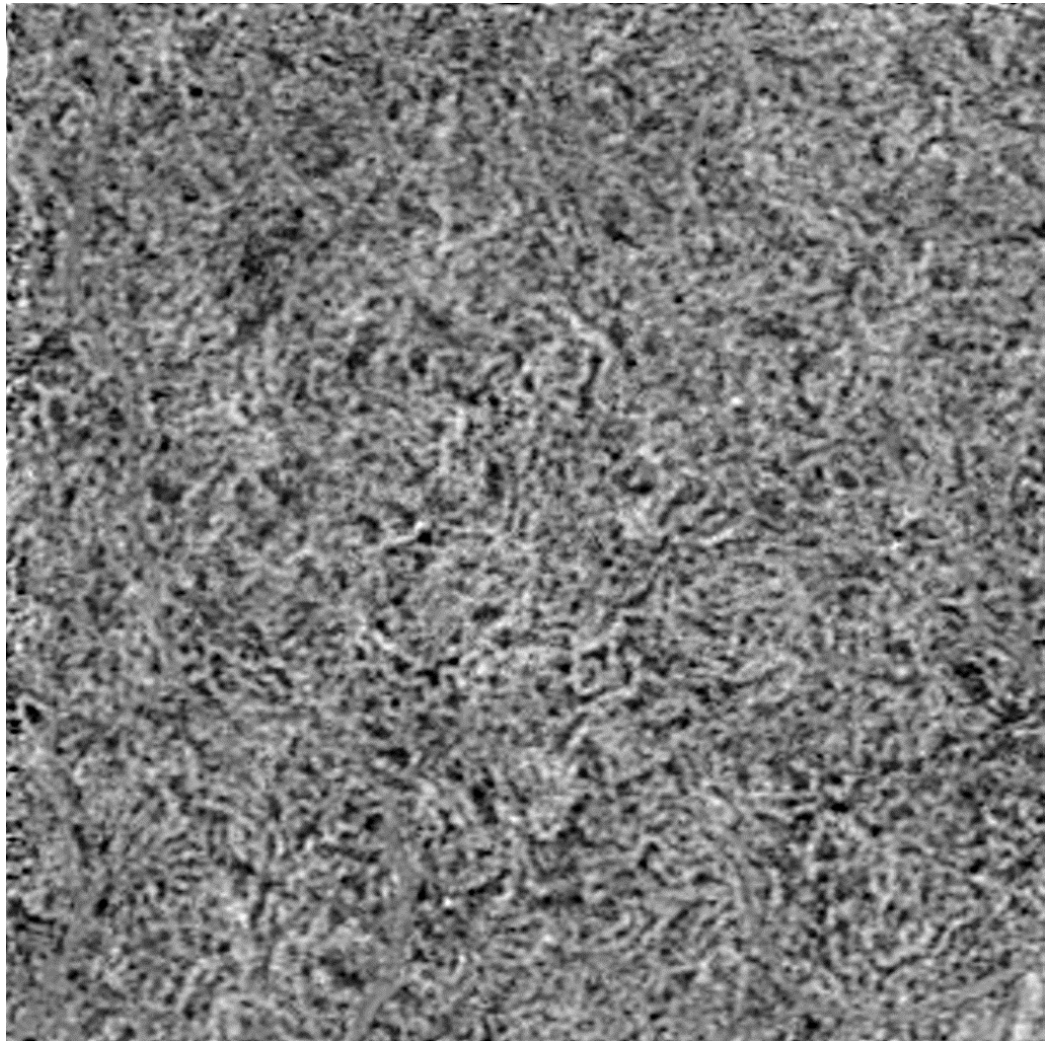

Images provided by:
Dr Ramin Tadayoni and Dr Sophie Bonnin
Hôpital Lariboisière, Paris, France

MHz SS-OCTA System and Imaging Protocols

- Modified ZEISS PLEX® Elite 9000
  - 1.7 MHz A-scan rate
  - 9 µm axial
  - 14 µm / 8 µm switchable lateral resolution (FWHM)
  - 5 mm imaging depth in tissue
  - 95 dB sensitivity
  - retina tracking

- Choriocapillaris Scan Patterns
  - 12 mm x 12 mm, 1280 (a-scans) x 1280 (b-scans) x 6 (b-scan repetitions)
  - 9 mm x 9 mm, 1024 (a-scans) x 1024 (b-scans) x 8 (b-scan repetitions)
  - 1.5 mm x 1.5 mm, 320 (a-scans) x 300 (b-scans) x 10 (b-scan repetitions)
    8 µm lateral resolution

MHz SS-OCTA of the choroidal vsculature



AMD patient
18 mm x 18 mm - single shot
2048 (a-scans) x 2048 (b-scans) x 2 (b-scan repetitions)

More on wide field OCT Angiography…

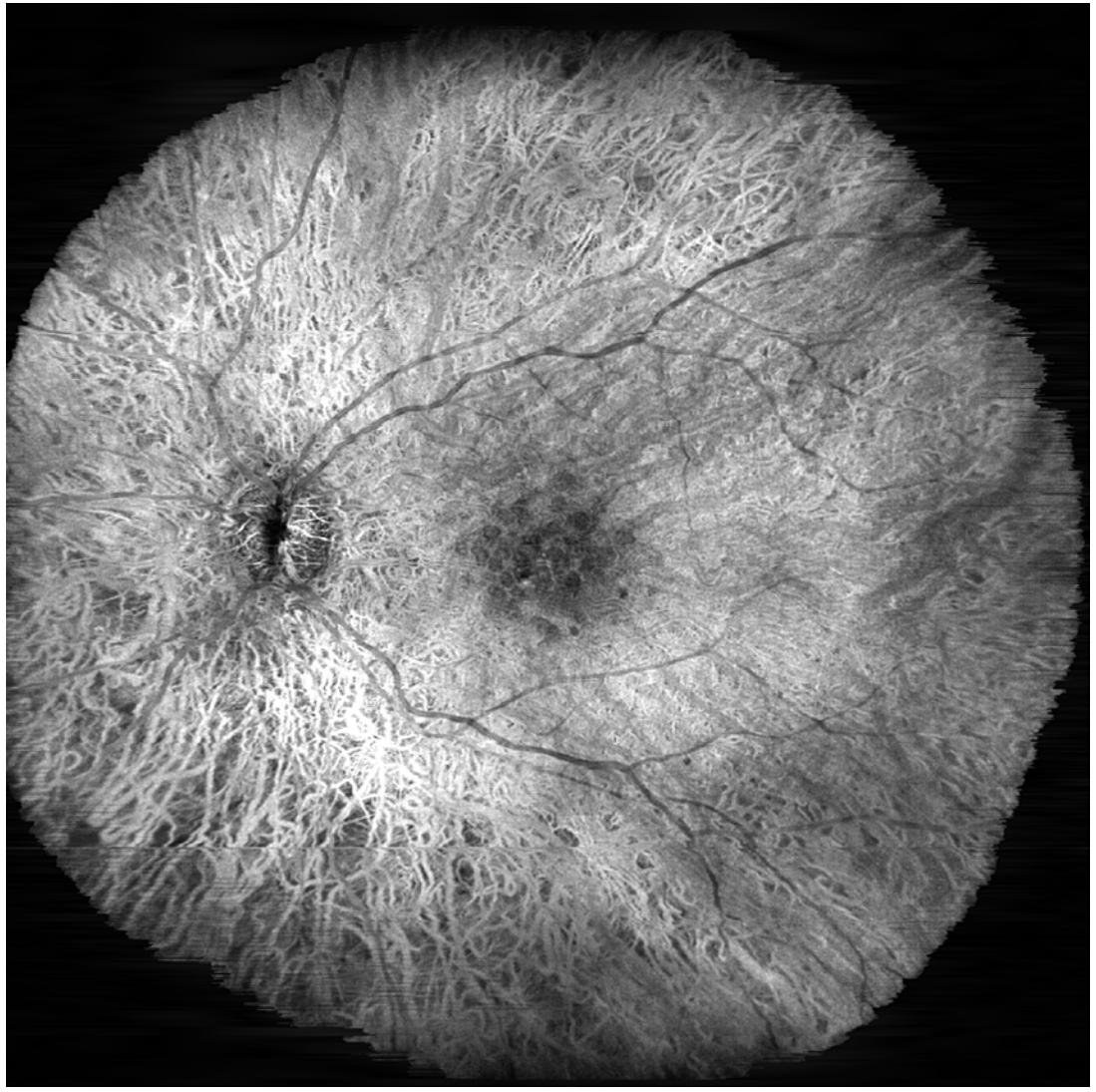

Imaging Conference:
Michael Niederleithner, et al., “3D deep learning algorithm for denoising OCTA volumes acquired at 1.68 MHz A-scan rate”
Poster Session II
May 14, 1:15 pm to 2:15 pm

ARVO:
Michael Niederleithner, et al., “Single shot wide field MHz swept source optical coherence tomography angiography”
Highlights of angiographic imaging
May 6, 5:15 pm to 6:45 pm

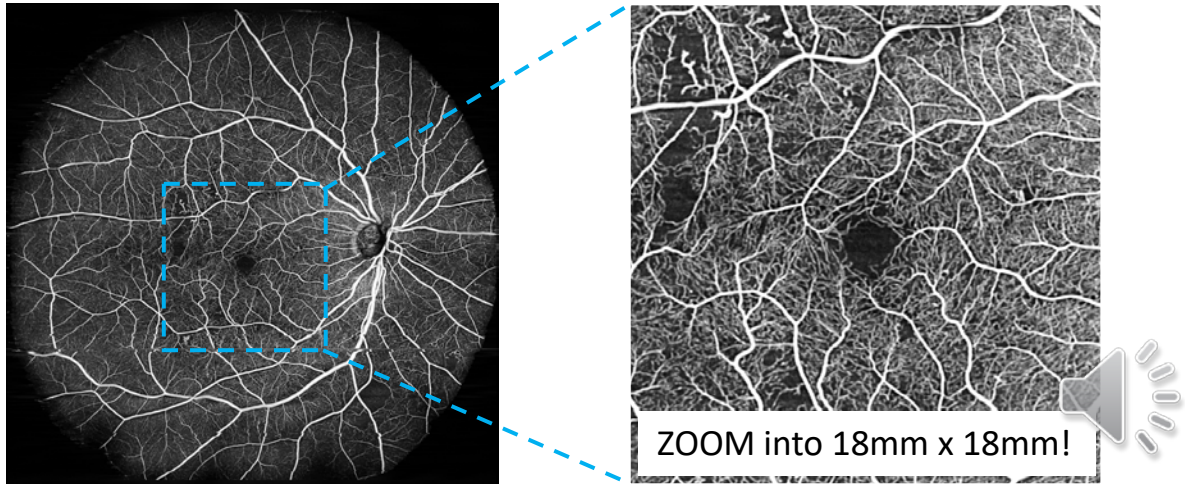

MHz SS-OCTA of the Choriocapillaris

29 yo healthy eye – single shot 9 mm x 9 mm

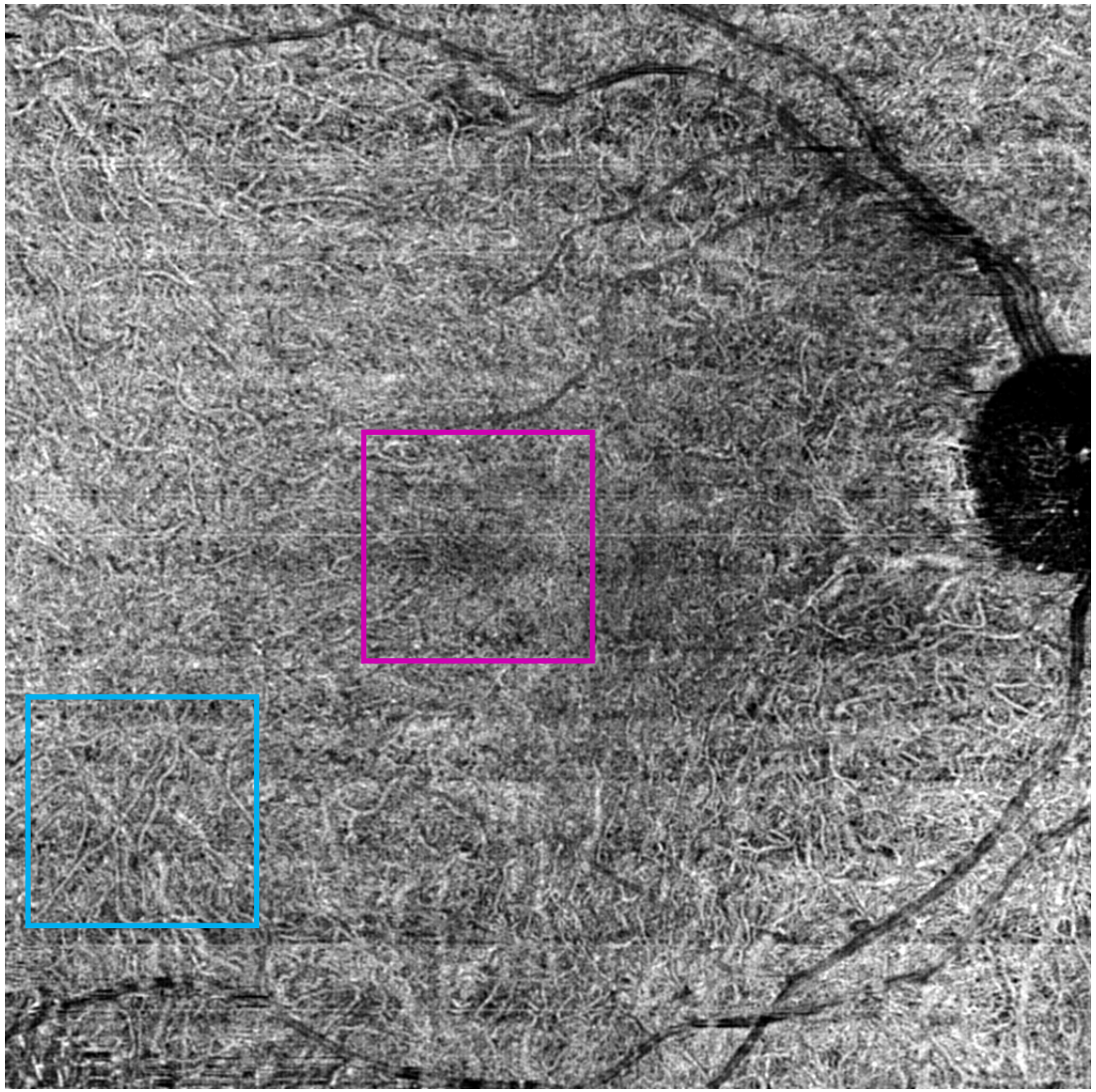



Ex-vivo confocal microscopy images of human choriocapillaris:

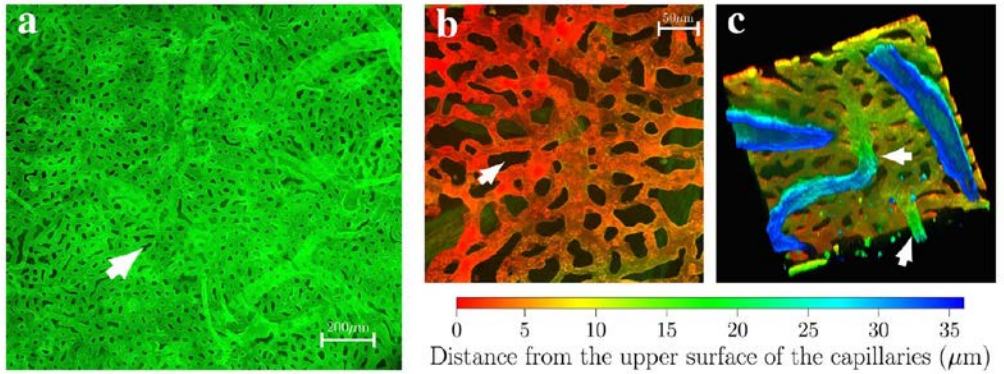

M.A. Zouache, I. Eames, C.A. Klettner, P.J. Luthert, “Form, shape and function: segmented blood flow in the choriocapillaris, “ Sci. Rep. 2016

MHz SS-OCTA of the Choriocapillaris

30 yo healthy eye – single shot 12 mm x 12 mm

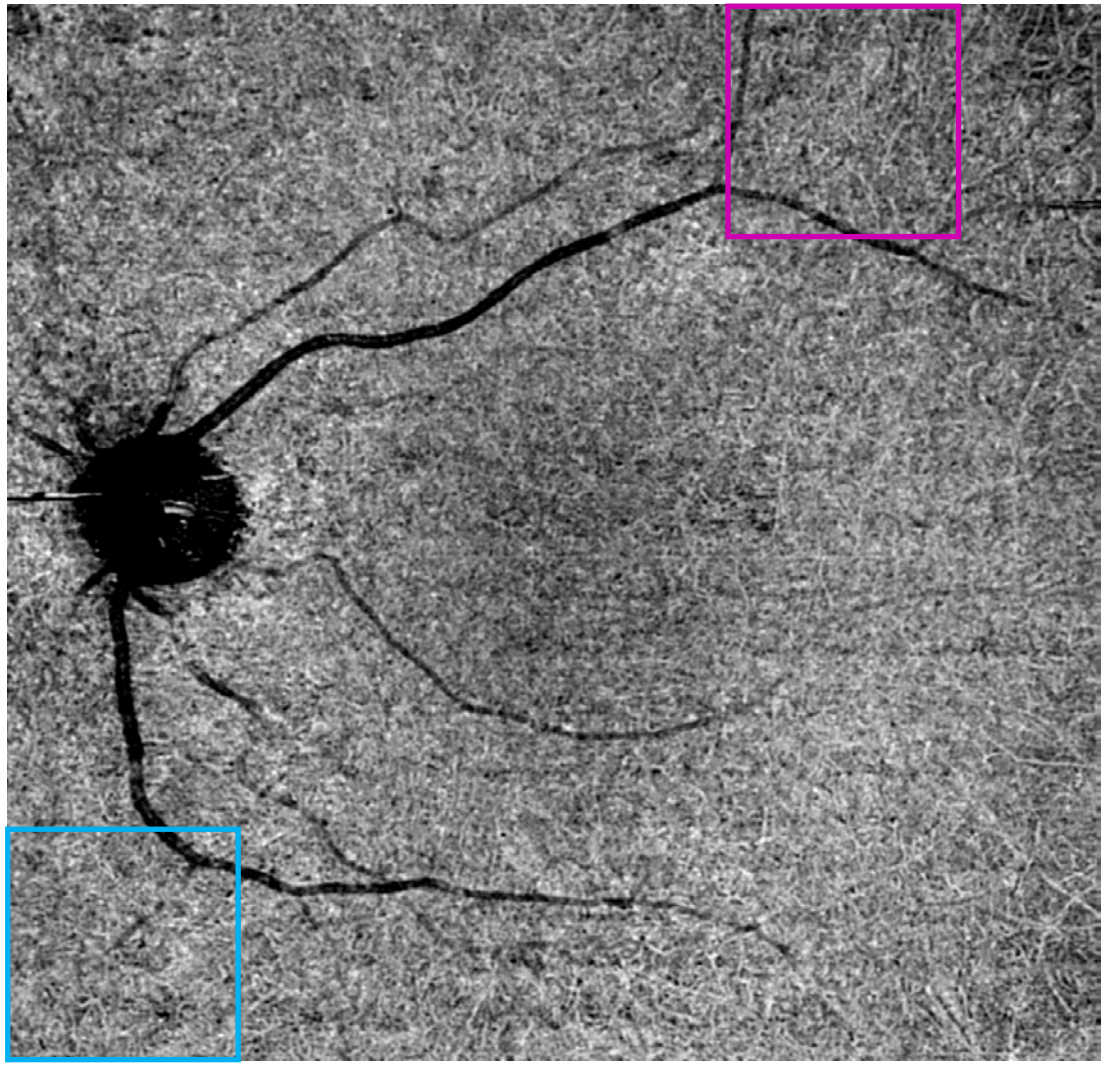





Ex-vivo confocal microscopy images of human choriocapillaris:

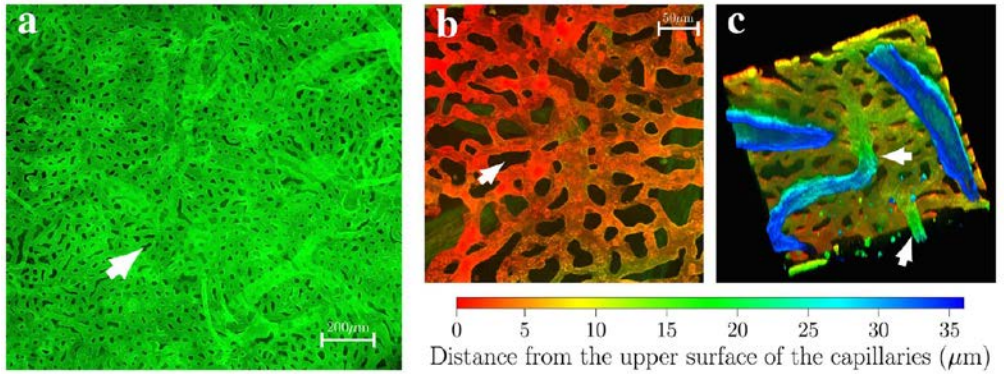

M.A. Zouache, I. Eames, C.A. Klettner, P.J. Luthert, “Form, shape and function: segmented blood flow in the choriocapillaris, “ Sci. Rep. 2016

Can we resolve capillaries in the macula?

30 yo healthy eye – single shot 12 mm x 12 mm

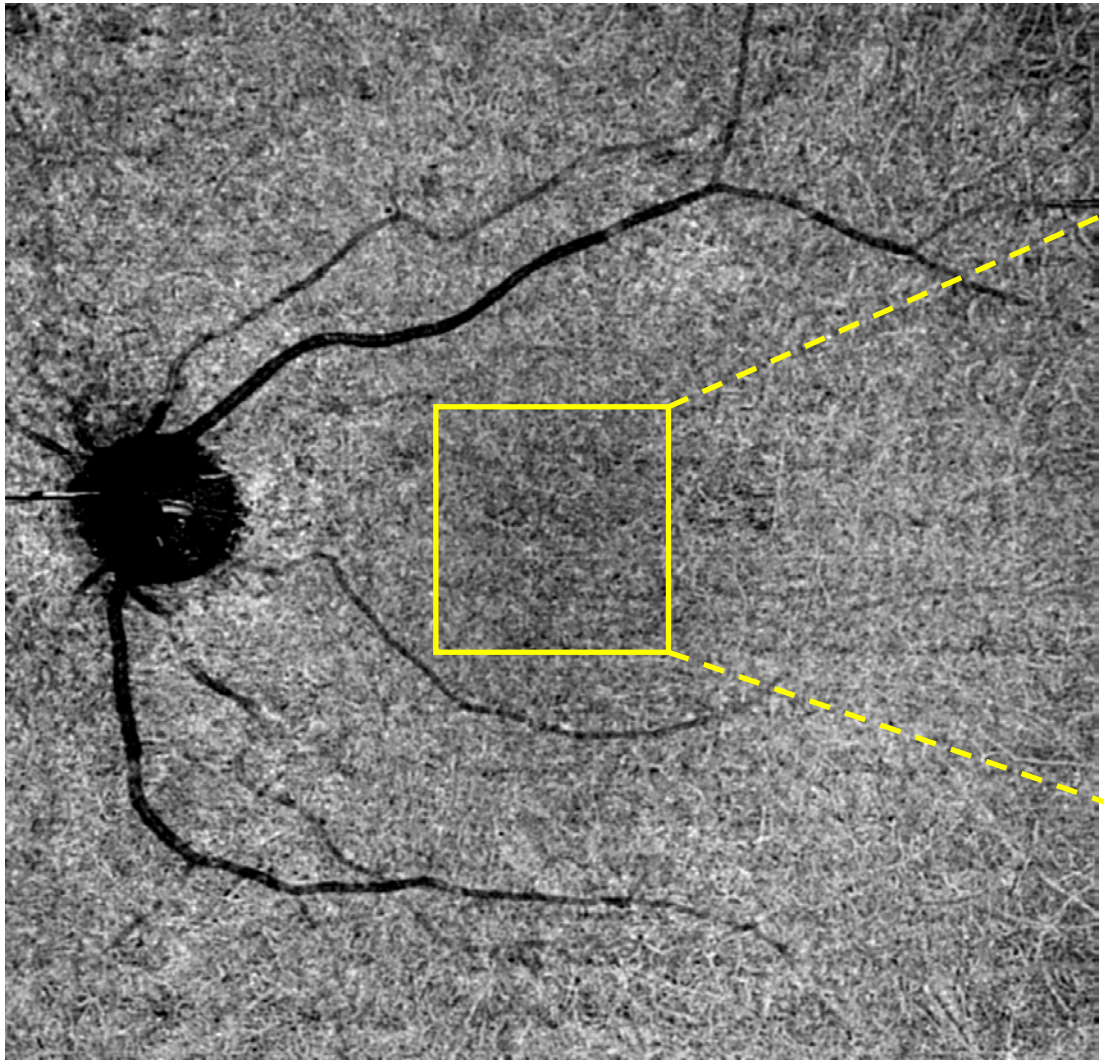

ZOOM IN



convolution of white noise with a Gaussian kernel



Can we resolve capillaries in the macula?

30 yo healthy eye – single shot 12 mm x 12 mm

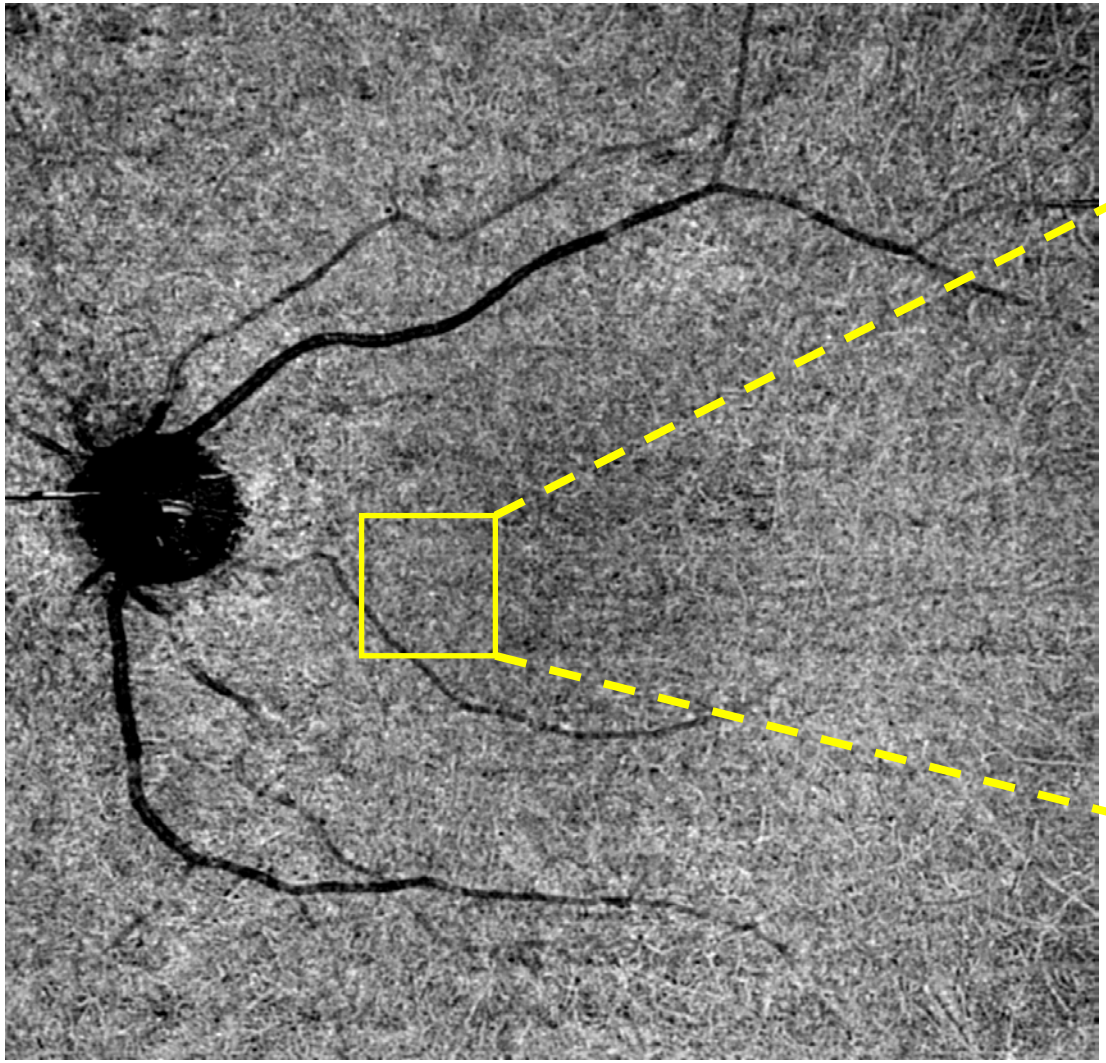

ZOOM IN

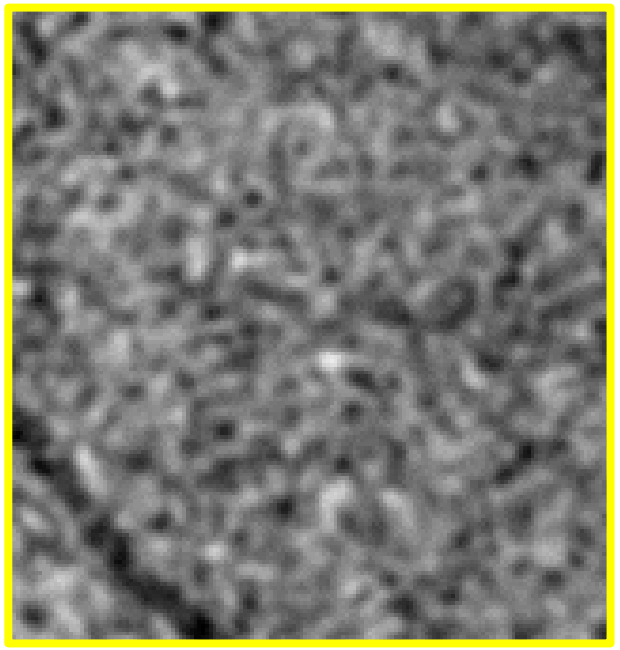

High Resolution Scan

8 µm lateral resolution
1.6 mm x 1.5 mm
320 x 300 x 10
[a-scans x b-scans x repetitions]

Can we resolve capillaries in the macula?

30 yo healthy eye – single shot 12 mm x 12 mm

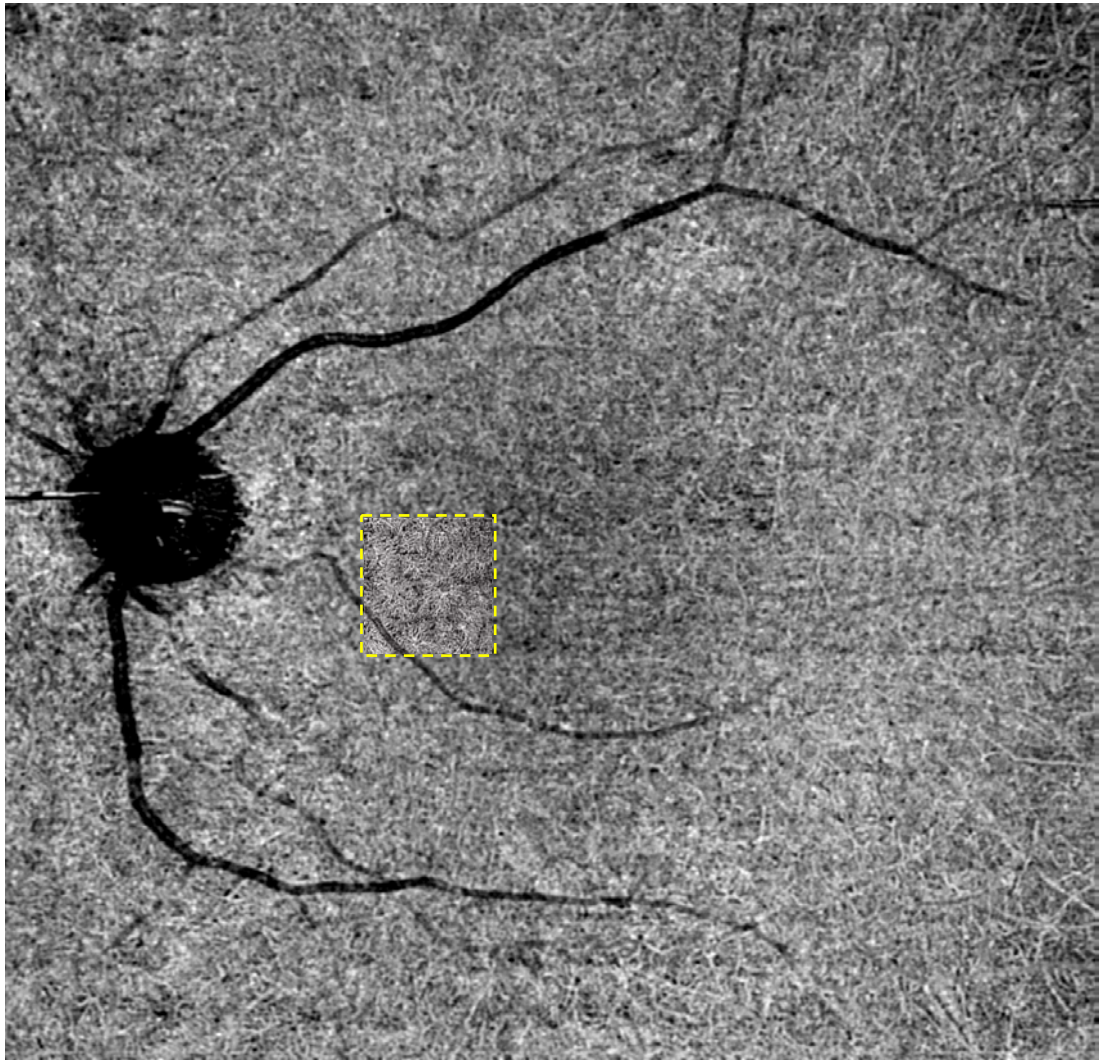

ZOOM IN

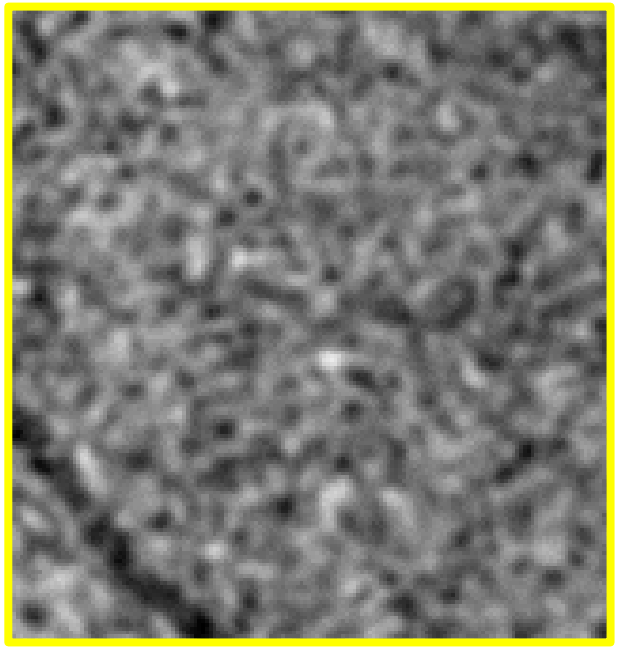

High Resolution Scan

8 µm lateral resolution
1.6 mm x 1.5 mm
320 x 300 x 10
[a-scans x b-scans x repetitions]

Implications for choriocapillaris flow void quantification

- Larger dark spots are likely to correspond to voids in the underlying, unresolved structure
- Although total flow void area has been demonstrated to be reproducible over time, the localization of individual small flow voids is not
- Absolute flow void areas are probably not reproducible across different systems

We recommend to exclude small flow voids in any quantitative analysis

input noise frame:





after convolution with Gaussian kernel:



increasing kernel size

Conclusion

- Choriocapillaris OCT angiography **images are prone to misinterpretation**
- **High lateral resolution** and **averaging** helps to resolve individual capillaries in the macula
- We **recommend the exclusion of small flow voids for the quantification** of the choriocapillaris for improved reproducibility

Acknowledgements

- The research group of **Dr. Donald Miller** at Indiana University
- **Dr Ramin Tadayoni** and **Dr Sophie Bonnin** at the Hôpital Lariboisière, Paris, France
- All colleagues at the Center for Medical Physics and Biomedical Engineering and ZEISS

CENTER FOR MEDICAL PHYSICS
AND BIOMEDICAL ENGINEERING
MEDICAL UNIVERSITY OF VIENNA

ZEISS

- External funding
  - MOON, H2020, Grant agreement ID: 732969

Moon H2020



MHz Swept Source Optical Coherence Tomography of the Choriocapillaris

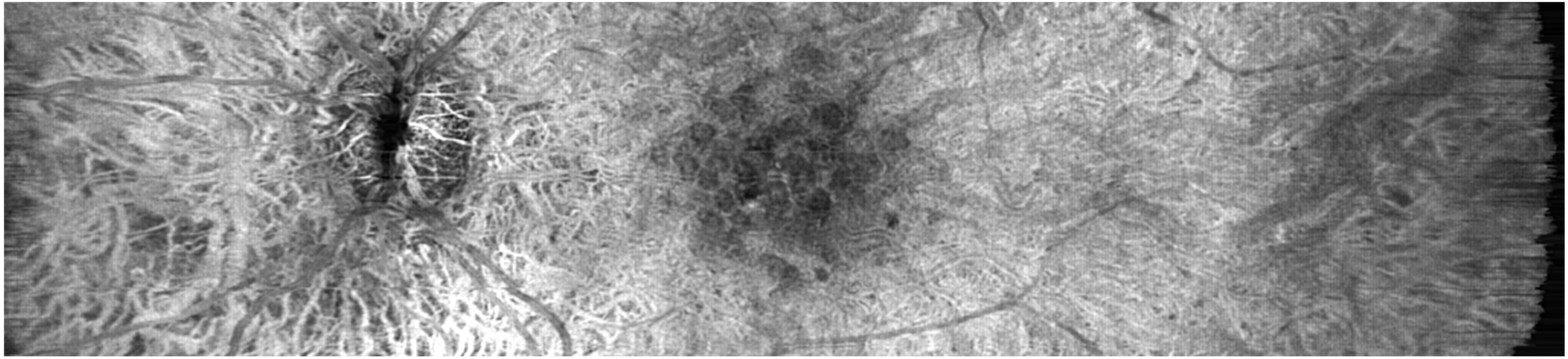

Contact: tilman.schmoll@zeiss.com