Joint ILM and RPE segmentation confidence map improves macular thickness analysis for low-cost OCT

Gabrielle Zacks, MSE; Homayoun Bagherinia, PhD; Conor Leahy, PhD; Taylor Shagam, BS; Simon Bello, PhD
Carl Zeiss Meditec Inc, Dublin, CA, United States

Poster #3528057

PURPOSE

- Robustness of macular thickness analysis (MTA) depends on the performance of inner limiting membrane (ILM) and retinal pigment epithelium (RPE) segmentation
- With a low-cost OCT, multiple scans are acquired to increase the probability of a successful MTA
- We propose a method to generate a joint ILM/RPE segmentation confidence map to automatically select the most reliable scans for analysis

METHODS

- 43 patients (70 eyes) with pathologies, including age-related macular degeneration, imaged on two devices:

Low-cost OCT prototype system	CIRRUS™ HD-OCT 5000
2-3 images per eye 5.78 x 7 mm OCT volume 512 A-scans per B-scan, 128 B-scans	1 image per eye (baseline) 6 x 6 mm OCT volume 512 A-scans per B-scan, 128 B-scans

- ILM and RPE layers segmented in all images acquired with low-cost device
- Confidence map generated for each layer from the processed image at each segmentation point
- Algorithm trained using confidence map data classified as high- or low-confidence, using a threshold to generate likelihood functions for Bayesian inference
- Joint segmentation confidence maps of each set of OCT volumes created by a posterior probability using the likelihood functions (Figure 1)
- Confidence index for a scan calculated by averaging the joint segmentation confidence maps over the ETDRS grid (Figure 2)
  - ETDRS grid = 3 concentric circles of 0.5, 1.5, and 2.89 mm radius at fovea center
- From 215 scans on the low-cost device and the corresponding confidence maps, 70 high- and 70 low-confidence MTAs of the same eyes (no scan overlap) were compared to 70 baseline CIRRUS MTAs of the same eyes

CONCLUSIONS

- We demonstrated a joint ILM/RPE segmentation confidence method that selects the best scans to use for MTA
- Multiple scans of the same eye can be acquired to increase the probability of acquiring a high-confidence scan
- Improved MTA in a low-cost device is important for detection and management of retinal diseases

Email: gabrielle.zacks@zeiss.com

Disclosures: GZ (E), HB (E), CL (E), TS (E), SB (E): Carl Zeiss Meditec, Inc.

RESULTS

Figure 1. *Joint segmentation confidence map generation process*

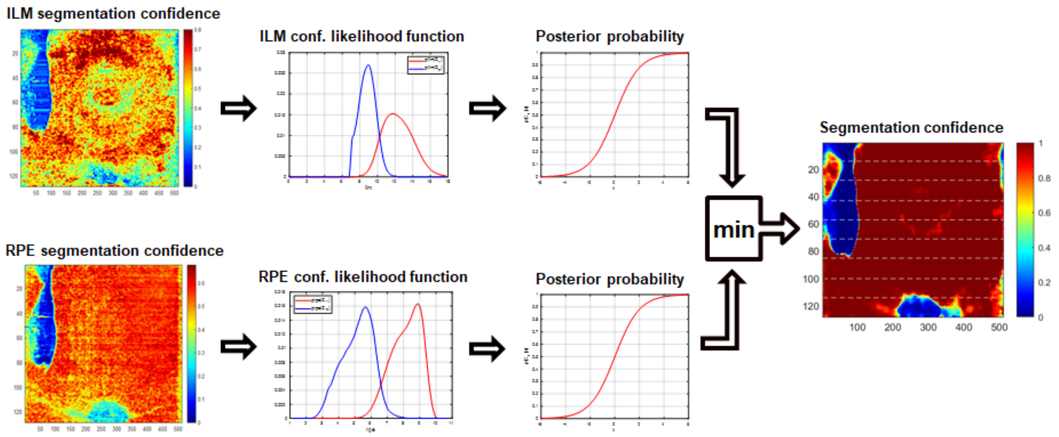

Figure 2. *From left: ETDRS grid sectors, confidence map, MTA*

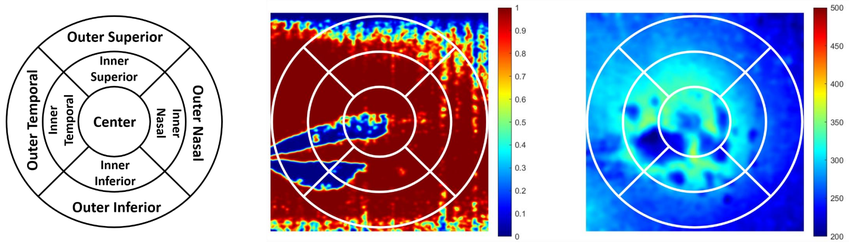

Below are the correlation and Bland-Altman agreement for each ETDRS subfield between the low-cost OCT and CIRRUS MTA. There was a dramatic improvement when high-confidence scans were used vs. low-confidence scans.

Sector	Low-cost OCT scans with high confidence vs. CIRRUS			Low-cost OCT scans with low confidence vs. CIRRUS		
	R^2 (Slope, intercept)	Mean difference [microns]	95% CI lower, upper limits [microns]	R^2 (Slope, intercept)	Mean difference [microns]	95% CI lower, upper limits [microns]
Central	0.80 (0.89, 34.9)	6.1	-26, 38	0.62 (0.81, 54.3)	6.0	-36, 48
Inner Nasal	0.98 (1.02, -1.52)	4.6	-2.9, 12	0.51 (0.95, 17.5)	0.29	-45, 46
Inner Superior	0.98 (1.0, 4.5)	5.0	-3.5, 13	0.70 (1.01, -3.90)	0.15	-40, 40
Inner Temporal	0.96 (0.97, 12.8)	4.6	-5.5, 15	0.69 (0.88, 37.4)	1.9	-30, 33
Inner Inferior	0.97 (0.99, 8.58)	5.3	-3.4, 14	0.41 (0.94, 19.7)	0.65	-56, 57
Outer Nasal	0.95 (1.0, 2.47)	4.0	-5.1, 13	0.28 (1.0, -2.12)	-1.9	-65, 61
Outer Superior	0.85 (1.02, -0.65)	4.7	-19, 29	0.32 (0.68, 93.9)	3.7	-55, 63
Outer Temporal	0.95 (1.02, -0.65)	5.3	-8.8, 19	0.66 (0.92, 21.5)	1.3	-38, 41
Outer Inferior	0.93 (1.02, -0.22)	5.4	-6.8, 18	0.35 (0.86, 37.9)	2.0	-51, 55