

Study Spotlight: Stability of CT LUCIA® 611P



Seeing beyond

CT LUCIA 611P provided patients with very satisfactory visual outcomes due to its stable position

Source



Title

Prospective study to compare axial position stability after fellow-eye implantation of 2 distinct intraocular lens designs



Authors

Julius Hienert, Nino Hirnschall, Manuel Ruiss, Marlie Ullrich, Hannah Zwickl, Oliver Findl



Publication

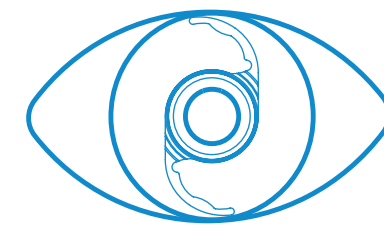
Journal of Cataract & Refractive Surgery: December 14, 2020 - Volume Publish Ahead of Print - Issue - doi: 10.1097/j.jcrs.0000000000000557

Methodology

IOL Stability

- CT LUCIA 611P compared to CT ASPHINA 409MP
- IOL stability and horizontal movement were determined by the difference in anterior chamber depth (ACD) measured 1 week, 1 month and 4–6 months post-operatively
- Monocular uncorrected and best corrected distance visual acuity and refraction were also measured

Sample Size

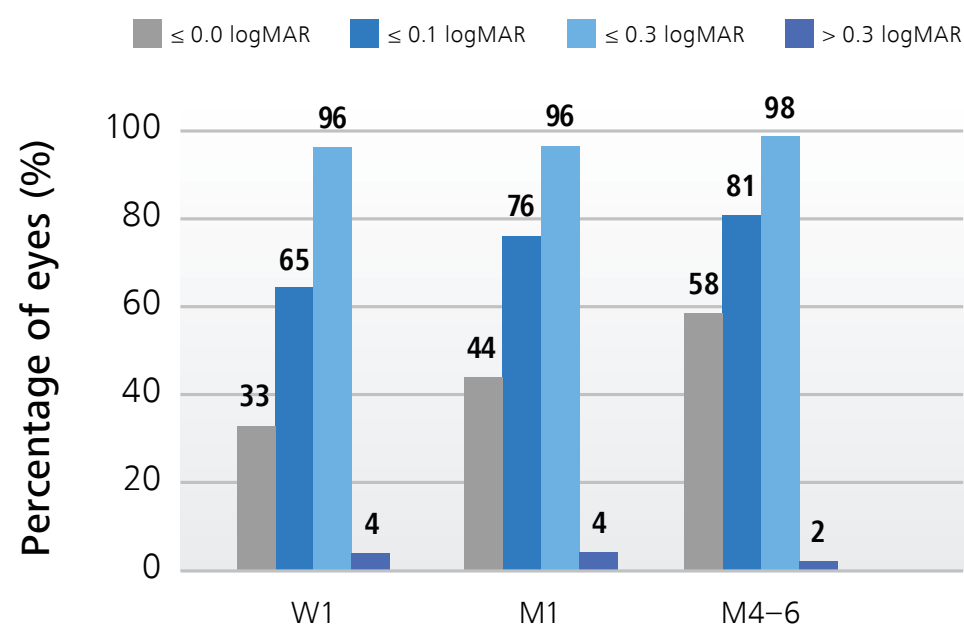


46 patients (92 eyes)

randomly implanted with both IOLs

Results

Uncorrected visual acuity at follow-up



CT LUCIA 611P

- Settled in a stable position within 1 week to 4–6 months post-operatively with a mean ACD variation of $0.14 \text{ mm} \pm 0.09 \text{ mm}$
- Provided patients with very satisfactory visual outcomes with a mean monocular uncorrected distance visual acuity of $0.06 \pm -0.14 \text{ logMAR}$ 4–6 months post-operatively
- No relevant or statistically significant differences were found in refraction or visual acuity between CT ASPHINA 409MP und CT LUCIA 611P