

Study Spotlight: Stability of CT LUCIA® 621P



Seeing beyond

Examining the stability of CT LUCIA 621P by measuring Anterior Chamber Depth (ACD)

Source



Title

Examining the stability of a new aspheric IOL (CT LUCIA 621P) in cataract patients



Author

Dr. Antonino Cuttitta



Publication

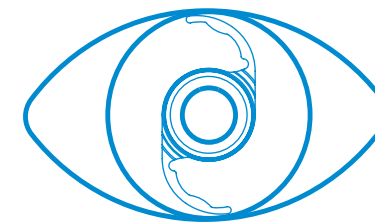
Ophthalmology Times Europe Journal: February 16, 2021

Methodology

IOL Stability

- IOL implanted in patients aged between 51 and 91 years
- No specific inclusion or exclusion criteria
- IOL Stability
 - Examined by measuring ACD with IOLMaster 700
 - Measured after 1 week and after 1 month

Sample Size



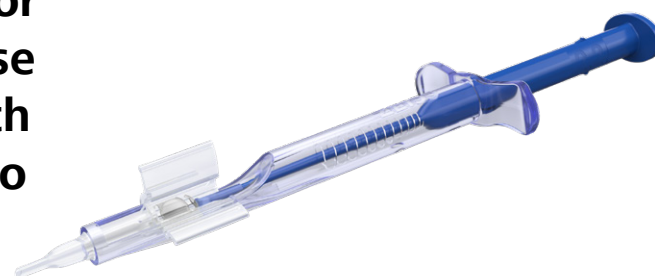60 eyes of 60 patients

Results

CT LUCIA 621P maintained stability in the capsular bag 1 week and 1 month after implantation and provided good refractive outcomes.



The redesigned injector system was easy to use and provided a smooth delivery of the IOL into the capsular bag.



Mean ACD after CT LUCIA 621P implantation

- At Week 1: 5.36 mm
- At Month 1: 5.34mm
- ▶ Good stability in the capsular bag, without any significant change in IOL position
- No complications
- No reported light-related disturbances
- Very good and consistent refractive outcomes
- ▶ Mean corrected Visual Acuity: 10/10

Injector system

- Very easy to use
- Minimal learning curve
- Good reliability