



Seeing beyond

# Asymptomatic Carotid Artery Stenosis

Images and diagnoses courtesy of Heron Eyecare, Adam Barron, OD

## Background

A 76-year-old, asymptomatic male presented for a routine eye examination. His medical and ocular histories were unremarkable except for an oral statin for hypercholesterolemia.

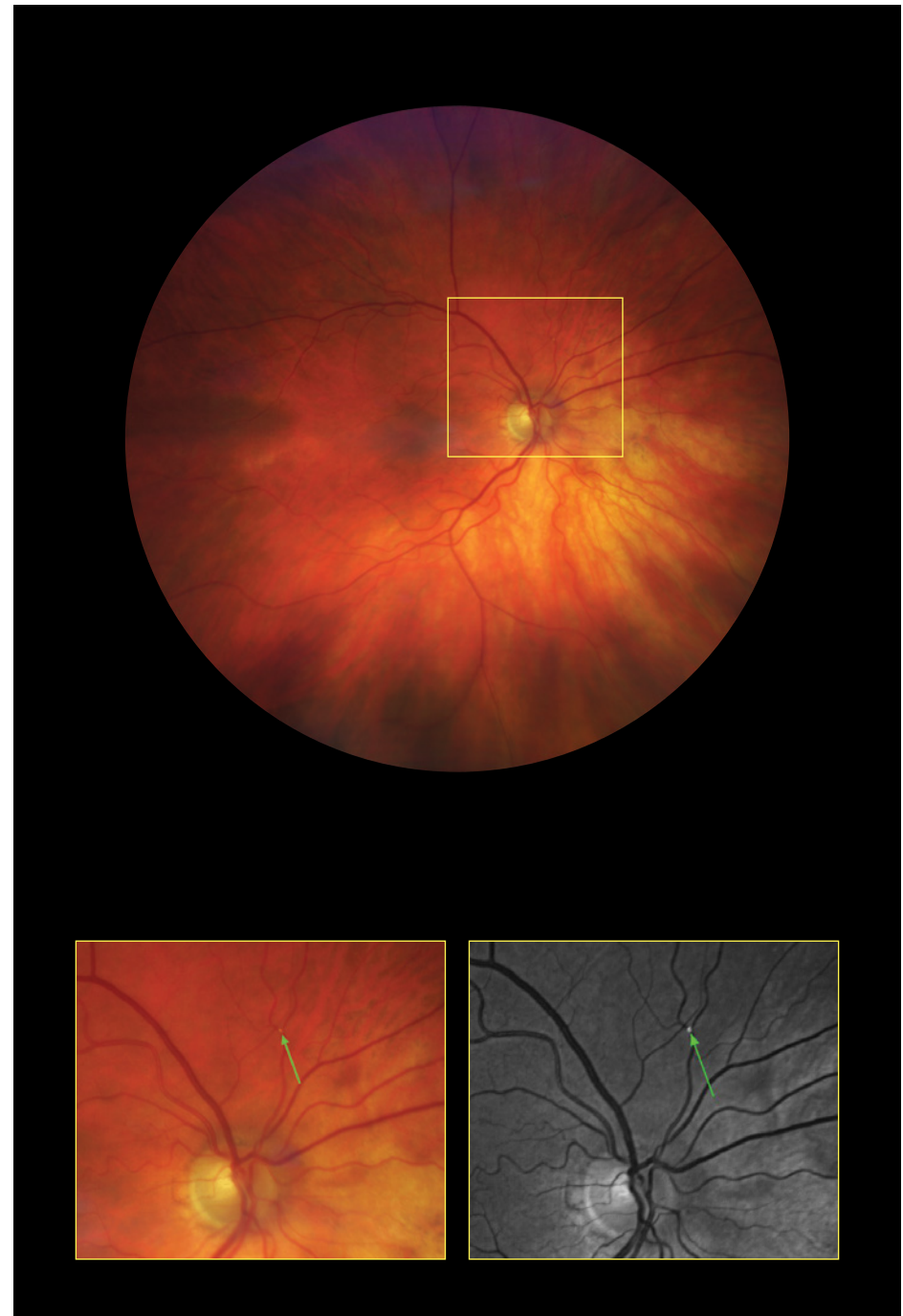
**Clinical Findings:** Fundus photography revealed a Hollenhorst plaque OD. An urgent carotid duplex showed carotid arteriolar stenosis of right 50-69%, left 15% due to arteriosclerosis. Patient is awaiting surgical evaluation for right carotid endarterectomy.

## Clinical efficiency and patient comfort

The stability and comfort of an integrated head/chin rest and less than 0.2-second image acquisition minimized artifacts and facilitated a confident diagnosis of the Hollenhorst plaque. A quickly taken true color, widefield image of the retina uncovered a subtle, incidental finding, giving practitioners the opportunity to prevent a potentially life-threatening event (figure 1).

## Color accuracy

CLARUS widefield retinal photography revealed a 100µm bright yellow refractile lesion located at the bifurcation of a right superotemporal retinal arteriole (figure 2). Green LED channel separation enhanced the contrast of retinal vasculature, demonstrating that this lesion was inside the lumen of the retinal arteriole (figure 3). The enhanced color and clarity of the image supported the confirmation of a well-defined Hollenhorst plaque.



The diagnoses provided by the healthcare professionals reflect only their personal opinions and experiences and do not necessarily reflect the opinions of any institution with whom they are affiliated. The healthcare professionals credited in this case study have a contractual relationship with Carl Zeiss Meditec, Inc., and have received financial compensation.

EN\_31\_025\_04101 / CAM.12564 © Carl Zeiss Meditec, Inc., 2020. All rights reserved.