

SMILE monovision – an effective and safe treatment for presbyopic ametropic patients

Jakob Siedlecki, MD

CASE HISTORY

A 53-year-old woman presented to the SMILE Eyes Clinic Linz, Austria, with a desire for spectacle independence. Being a myope, she had been wearing contact lenses for years, but had switched to bifocal glasses 7 months earlier due to contact lens intolerance. Now, she was complaining about visual distortion and needing to use different glasses for distance, intermediate, and near vision, which was especially problematic at her job where she worked mostly at a computer. Wearing glasses was also not compatible with her hobbies that consisted mostly of water sports. The patient had researched treatment options and stated that she was particularly interested in corneal laser correction of her ametropia.

She underwent a standardized preoperative assessment protocol that included objective, subjective and cycloplegic refraction. She had no astigmatism. Manifest refractive spherical equivalent (MRSE) was -3.00 diopters (D) OD and -2.25 D OS.

Slit-lamp biomicroscopy and fundoscopy were performed as well as retinal (CIRRUS HD-OCT, Carl Zeiss Meditec AG, Jena, Germany) and corneal imaging (Pentacam, OCULUS Optikgeräte GmbH, Wetzlar, Germany) to rule out concomitant eye conditions (eg., maculopathies or diseases reducing corneal biomechanical stability). There were no remarkable findings in either eye, and the crystalline lens was clear OU. Although the patient reported using lubricant eye drops for occasional dry eye symptoms, the conjunctival and corneal surface examinations were also unremarkable.

Monocular distance corrected visual acuity (DCVA) measured at 4 meters was 20/16 (Snellen equivalent) OU, and reading vision measured at 40 cm was 20/50 (Jaeger 5) OU. Uncorrected visual acuity was 20/400 at distance and 20/20 (Jaeger 1+) at near.

The patient was thoroughly informed about the options available to treat her myopia and presbyopia. Because of the blurred vision she experienced with bifocal glasses and fear of developing halos and glare, she declined refractive lens exchange with implantation of multifocal intraocular lenses (IOLs). The possible risks of intraocular surgery and a wish to maintain her natural crystalline lens also contributed to her refusal of refractive lens exchange.

Corneal refractive surgery mini-monovision with small-incision lenticule extraction (SMILE) was offered as an alternative. The patient was thoroughly informed about the loss of distance vision in the near corrected eye, loss of near vision in the distance corrected eye, the possible loss of stereoacuity and binocular summation, and the possibility of requiring glasses for certain tasks, such as driving at night or reading small print. In addition, mini-monovision was simulated by fully correcting both eyes for optimal distance vision and then gradually pushing her non-dominant right eye towards myopia in steps of 0.25 D. The patient tolerated up to -1.25 D myopia in the non-dominant eye without suffering from binocular disturbance because of cross-blur.

SMILE was performed as a standard procedure using a 500 kHz femtosecond laser (VisuMax, Carl Zeiss Meditec AG, Jena, Germany). Target refractions were plano OD and -1.25 D OS. Minimum lenticule thickness was increased from 10 to 30 μ m considering the low dioptric correction needed and our group's report that increasing minimum lenticule thickness is associated with improved safety, predictability and induction of higher-order aberrations.¹ The surgery was completed successfully without any intraoperative complications.

At 1 week, MRSE was -1.38 D OD and +0.25 D OS with -0.25 D of cylinder OU. Uncorrected distance visual acuity was 20/63 OD and 20/16 OS. As expected with mini-monovision, binocular summation was preserved, resulting in binocular UDVA of 20/12.5. Binocular uncorrected reading visual acuity was 20/25 (Jaeger 1).

Figure 1 compares the patient's preoperative and postoperative vision. Note the improvement postoperatively in UDVA and CDVA along with her better uncorrected near VA postoperatively compared with her preoperative distance-corrected near VA. Consistent with the low anisometropia that was present preoperatively, the patient reported only mild bilateral blur.

At 1 month, the patient stated that the blur had progressively diminished. Full neuroadaptation had occurred, and the patient said she was very satisfied with her outcome. She was last seen 12 months after SMILE, and during the available follow-up, MRSE and visual acuity remained

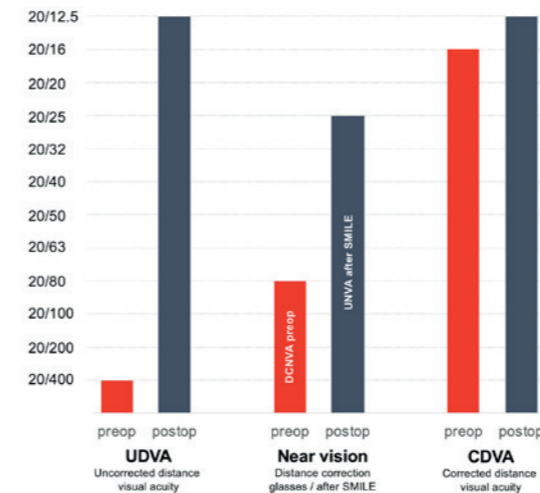


Figure 1. Visual acuity results from preoperative testing and at 1 week post-SMILE.

stable. The patient reported that except for using reading glasses when reading for a prolonged period of time, she had no need for glasses.

DISCUSSION

Many patients presenting with an interest in corneal refractive surgery to achieve spectacle independence are young and pre-presbyopic. In our clinic, however, up to 20 % of patients undergoing SMILE and other corneal refractive procedures are 45 years of age and older.

Whereas presbyopia correction is often presented to patients needing cataract surgery, this opportunity is less often discussed during preoperative counseling for corneal refractive surgery. Yet, the development of presbyopia accompanied by a need for reading glasses causes a reduction in quality of life.² Therefore, preoperative education for patients with latent or manifest presbyopia who are interested in corneal refractive surgery should include the possibility of simultaneous treatment for ametropia and presbyopia.

Monovision excimer laser refractive surgery has a long history of use and has been shown to provide satisfactory results with high levels of spectacle independence.³ Compared to refractive lens exchange with implantation of a presbyopia-correcting IOL, laser corneal refractive surgery may be particularly attractive to patients with a clear crystalline lens because it avoids vision-threatening risks inherent to the intraocular procedure, which include endophthalmitis, retinal detachment, and cystoid macular oedema. Corneal refractive surgery also largely preserves ocular anatomy and offers the potential for enhancement.

SMILE is a newer laser corneal refractive surgery approach for the safe and effective treatment of myopia and myopic astigmatism.⁴ As a flapless procedure, SMILE has advantages compared with LASIK, including better preservation of corneal biomechanics, lower risk of dry eye, and less discomfort postoperatively.⁴

This case highlights a role for SMILE to provide monovision and spectacle independence for presbyopic patients with myopia or myopic astigmatism. The excellent outcomes achieved in the patient in this case are representative of those we recently reported in a retrospective review conducted by Dr. Luft from our group, analyzing outcomes in 49 presbyopic patients seeking surgical correction of myopia or myopic astigmatism.⁵ In our published series, binocular UDVA was 20/20 or better in 90% of patients and 20/25 or better in all patients; mean binocular uncorrected near visual acuity was Jaeger 1 (20/25 Snellen equivalent). Eighty-four percent of patients achieved complete spectacle independence and 92% reported no need for reading glasses. Our experience is also consistent with that of investigators from the Nethradhama Eye Hospital, Bangalore, India, who reported satisfactory visual outcomes for near, intermediate, and distance vision accompanied by high levels of spectacle independence and patient satisfaction in a series of 18 myopic presbyopic patients treated with SMILE monovision.⁶

CONCLUSION

SMILE monovision is a safe and effective treatment for presbyopic patients with myopia or myopic astigmatism who are interested in gaining spectacle independence. For surgeons who are experienced with SMILE, its application for monovision requires no additional skills nor any deviation from the standard technique apart from introducing mini-monovision into target refraction planning.

Whether achieved using pseudophakic monofocal IOLs or laser corneal surgery, however, monovision has visual consequences that can limit patient acceptance and satisfaction. To increase the likelihood of success, refractive surgeons should establish proper patient expectations by providing thorough preoperative counselling and perform an in-office simulation of monovision to assess tolerance. Correct identification of the dominant eye and limiting anisometropia to 1.5 D to maintain better stereopsis are also pivotal factors for patient satisfaction. In addition, we recommend aiming for plano as the refractive target in the dominant eye because unsatisfactory distance vision due to undercorrection in the dominant eye is the most common reason for retreatment in monovision.⁷

Dr. Siedlecki, Resident in Ophthalmology, Ludwig-Maximilians-University of Munich, Munich, Germany. He is not a paid consultant for Carl Zeiss Meditec AG.

References

- Siedlecki J, Luft N, Keidel L, et al. Variation of lenticule thickness for SMILE in low myopia. *J Refract Surg.* 2018;34(7):453-459.
- Goertz AD, Stewart WC, Burns WR, Stewart JA, Nelson LA. Review of the impact of presbyopia on quality of life in the developing and developed world. *Acta Ophthalmol.* 2014;92(6):497-500.
- Mahrous A, Ciralsky JB, Lai EC. Revisiting monovision for presbyopia. *Curr Opin Ophthalmol.* 2018;29(4):313-317.
- Ganesh S, Brar S, Arra RR. Refractive lenticule extraction small incision lenticule extraction: A new refractive surgery paradigm. *Indian J Ophthalmol.* 2018;66(1):10-19.
- Luft N, Siedlecki J, Sekundo W, et al. Small incision lenticule extraction (SMILE) monovision for presbyopia correction. *Eur J Ophthalmol.* 2018;28(3):287-293.
- Ganesh S, Brar S. Small-incision lenticule extraction monovision as a treatment modality for myopic individuals with presbyopia: six-month clinical outcomes. Paper presented at the 2018 ASCRS Symposium; April 15, 2018; Washington, DC.
- Braun EH, Lee J, Steinert RF. Monovision in LASIK. *Ophthalmology* 2008;115(7):1196-1202.

Sponsored by Carl Zeiss Meditec AG